

## CLINICAL PRACTICE GUIDELINE DOCUMENT

# European Society for Vascular Surgery (ESVS) 2025 Clinical Practice Guidelines on the Management of Vascular Trauma<sup>☆</sup>

Carl Magnus Wahlgren<sup>a,\*</sup>, Christopher Aylwin<sup>a</sup>, Ross A. Davenport<sup>a</sup>, Lazar B. Davidovic<sup>a</sup>, Joseph J. DuBose<sup>a</sup>, Christine Gaarder<sup>a</sup>, Catherine Heim<sup>a</sup>, Vincent Jongkind<sup>a</sup>, Joakim Jørgensen<sup>a</sup>, Stavros K. Kakkos<sup>a</sup>, David T. McGreevy<sup>a</sup>, Maria Antonella Ruffino<sup>a</sup>, Melina Vega de Ceniga<sup>a</sup>, Pirkka Vikatmaa<sup>a</sup>, Jean-Baptiste Ricco<sup>a</sup>, Karim Brohi<sup>a</sup>

ESVS Guidelines Committee<sup>b</sup>, George A. Antoniou, Jonathan R. Boyle, Raphaël Coscas, Nuno V. Dias, Barend M.E. Mees, Santi Trimarchi, Christopher P. Twine, Isabelle Van Herzele, Anders Wanhainen

Document Reviewers<sup>c</sup>, Paul Blair, Ian D.S. Civil, Michael Engelhardt, Erica L. Mitchell, Gabriele Piffaretti, Sabine Wipper

**Objective:** The European Society for Vascular Surgery (ESVS) has developed clinical practice guidelines for the care of patients with vascular trauma with the aim of assisting physicians in selecting the optimal management strategy.

**Methods:** The guidelines are based on scientific evidence completed with expert opinion. By summarising and evaluating the best available evidence, recommendations for the evaluation and treatment of patients have been formulated. The recommendations are graded according to the ESVS evidence grading system, where the strength (class) of each recommendation is graded from I to III, and the letters A to C mark the level of evidence.

**Results:** A total of 105 recommendations have been issued on the following topics: general principles for vascular trauma care and resuscitation including technical skill sets, bleeding control and restoration of perfusion, graft materials, and imaging; management of vascular trauma in the neck, thoracic aorta and thoracic outlet, abdomen, and upper and lower extremities; post-operative considerations after vascular trauma; and paediatric vascular trauma. In addition, unresolved vascular trauma issues and the patients' perspectives are discussed.

**Conclusion:** The ESVS clinical practice guidelines provide the most comprehensive, up to date, evidence based advice to clinicians on the management of vascular trauma.

Article history: Received 22 November 2024, Accepted 9 December 2024, Available online XXX

© 2024 The Authors. Published by Elsevier B.V. on behalf of European Society for Vascular Surgery. This is an open access article under the CC BY-NC-ND license (<http://creativecommons.org/licenses/by-nc-nd/4.0/>).

## TABLE OF CONTENTS

Abbreviations and acronyms	3
Summary of recommendations	4
1. Methodology	7
1.1. Introduction	7
1.2. Guideline Writing Committee	7
1.3. Literature search and selection	8
1.4. Evidence and recommendation grading criteria	8
1.5. Review process	8
1.6. Limitations	8
2. Vascular trauma general considerations	9
2.1. Vascular trauma epidemiology	9
2.2. General principles for vascular trauma care	9

<sup>☆</sup> For a full list of the authors' affiliations, please refer to [Appendix B](#).

<sup>a</sup> **Guideline Writing Committee:** Carl Magnus Wahlgren (Chair; Stockholm, Sweden), Christopher Aylwin (London, UK), Ross A. Davenport (London, UK), Lazar B. Davidovic (Belgrade, Serbia), Joseph J. DuBose (Austin, TX, USA), Christine Gaarder (Oslo, Norway), Catherine Heim (Lausanne, Switzerland), Vincent Jongkind (Amsterdam, the Netherlands), Joakim Jørgensen (Oslo, Norway), Stavros K. Kakkos (Patras, Greece), David T. McGreevy (Örebro, Sweden), Maria Antonella Ruffino (Lugano, Switzerland), Melina Vega de Ceniga (Galdakao, Leioa, and Barakaldo, Spain), Pirkka Vikatmaa (Helsinki, Finland), Jean-Baptiste Ricco (Co-Chair, Poitiers, France), Karim Brohi (Co-Chair; London, UK).

<sup>b</sup> **ESVS Guidelines Committee:** George A. Antoniou (Manchester, UK), Jonathan R. Boyle (Cambridge, UK), Raphaël Coscas (Boulogne-Billancourt, France), Nuno V. Dias (Malmö, Sweden), Barend M.E. Mees (Maastricht, the Netherlands), Santi Trimarchi (Milan, Italy), Christopher P. Twine (Bristol, UK), Isabelle Van Herzele (Ghent, Belgium), Anders Wanhainen (Uppsala and Umeå, Sweden).

<sup>c</sup> **Document Reviewers:** Paul Blair (Belfast, Northern Ireland, UK), Ian D.S. Civil (Auckland, New Zealand), Michael Engelhardt (Ulm, Germany), Erica L. Mitchell (Memphis, TN, USA), Gabriele Piffaretti (Varese, Italy), Sabine Wipper (Innsbruck, Austria).

\* Corresponding author. Department of Vascular Surgery, Karolinska Institutet and Karolinska University Hospital, 171 76 Stockholm, Sweden.

E-mail address: [carl.wahlgren@regionstockholm.se](mailto:carl.wahlgren@regionstockholm.se) (Carl Magnus Wahlgren).

1078-5884/© 2024 The Authors. Published by Elsevier B.V. on behalf of European Society for Vascular Surgery. This is an open access article under the CC BY-NC-ND license (<http://creativecommons.org/licenses/by-nc-nd/4.0/>).

<https://doi.org/10.1016/j.ejvs.2024.12.018>

2.3.	<i>Who should perform vascular trauma surgery?</i>	10
2.4.	<i>What technical skill set is required for vascular trauma surgery?</i>	10
2.5.	<i>When are endovascular therapies required for vascular trauma?</i>	10
2.6.	<i>What approach to resuscitation should be used for vascular trauma?</i>	11
2.7.	<i>Use of tourniquets for temporary bleeding control</i>	11
2.8.	<i>Resuscitative endovascular balloon occlusion of the aorta</i>	12
2.9.	<i>What diagnostic imaging should be used for the emergency diagnosis of vascular trauma?</i>	12
2.10.	<i>European Society for Vascular Surgery grading system for arterial trauma</i>	13
2.11.	<i>How should perfusion be restored as an emergency in vascular trauma?</i>	14
2.12.	<i>Vascular shunts vs. definitive repair</i>	14
2.13.	<i>Which technique should be used for vascular graft reconstruction?</i>	15
2.14.	<i>Which graft materials should be used for arterial reconstruction?</i>	15
<b>3.</b>	<b>Neck vascular trauma</b>	16
3.1.	<i>Penetrating neck injury</i>	16
3.1.1.	<i>Clinical presentation</i>	16
3.1.2.	<i>Diagnostic imaging</i>	16
3.1.3.	<i>Management</i>	17
3.1.3.1.	<i>Penetrating carotid artery injury</i>	17
3.1.3.2.	<i>Penetrating vertebral artery injury</i>	17
3.1.3.3.	<i>Penetrating cervical venous injury</i>	18
3.2.	<i>Blunt cervical vascular injury</i>	18
3.2.1.	<i>Clinical presentation</i>	18
3.2.2.	<i>Diagnostic imaging</i>	19
3.2.3.	<i>Management</i>	19
3.2.3.1.	<i>Blunt carotid artery injury</i>	19
3.2.3.2.	<i>Blunt vertebral artery injury</i>	20
3.2.3.3.	<i>Antithrombotic therapy</i>	21
3.2.3.4.	<i>Surveillance of blunt cervical vascular injury</i>	21
3.2.4.	<i>Post-operative antithrombotic therapy</i>	22
<b>4.</b>	<b>Thoracic aorta and thoracic outlet vascular trauma</b>	22
4.1.	<i>Blunt thoracic aortic injury</i>	22
4.1.1.	<i>Clinical presentation</i>	22
4.1.2.	<i>Diagnostic imaging</i>	22
4.1.3.	<i>Grading of thoracic aortic lesions</i>	23
4.1.4.	<i>Management of thoracic aortic injury</i>	23
4.1.4.1.	<i>Minor aortic injuries</i>	23
4.1.4.2.	<i>Pseudoaneurysms</i>	24
4.1.4.3.	<i>Severe aortic injury</i>	25
4.1.5.	<i>Operative management</i>	25
4.1.5.1.	<i>Endovascular repair</i>	25
4.1.5.1.1.	<i>Stent graft oversizing</i>	25
4.1.5.1.2.	<i>Left subclavian artery coverage</i>	26
4.1.5.2.	<i>Open surgical repair</i>	26
4.1.6.	<i>Long term follow up</i>	27
4.2.	<i>Blunt injuries to the aortic arch vessels</i>	28
4.3.	<i>Penetrating thoracic aortic injury</i>	28
4.4.	<i>Blunt and penetrating subclavian artery injury</i>	28
<b>5.</b>	<b>Abdominal vascular trauma</b>	28
5.1.	<i>Clinical presentation</i>	28
5.2.	<i>Diagnostic imaging</i>	29
5.3.	<i>Intra-operative management of retroperitoneal haematoma</i>	29
5.4.	<i>Abdominal aorta</i>	30
5.4.1.	<i>Non-operative management</i>	30
5.4.2.	<i>Open surgical repair</i>	30
5.4.3.	<i>Endovascular repair</i>	30
5.5.	<i>Iliac arteries</i>	31
5.5.1.	<i>Open surgical repair</i>	31
5.5.2.	<i>Endovascular repair</i>	31
5.6.	<i>Mesenteric arteries</i>	31
5.6.1.	<i>Operative management</i>	32
5.6.2.	<i>Non-operative management</i>	32
5.7.	<i>Renal arteries</i>	32
5.7.1.	<i>Non-operative management</i>	32
5.7.2.	<i>Open surgical and endovascular management</i>	32
5.8.	<i>Inferior vena cava and major abdominal veins</i>	33
5.8.1.	<i>Inferior vena cava</i>	33
5.8.1.1.	<i>Non-operative management</i>	33
5.8.1.2.	<i>Operative management</i>	33
5.8.2.	<i>Iliac veins</i>	34
5.8.3.	<i>Portal vein and superior mesenteric vein</i>	34
5.8.4.	<i>Renal veins</i>	34

6.	<b>Extremity vascular trauma</b>	34
6.1.	<i>Clinical presentation</i>	34
6.1.1.	Physical examination	34
6.1.2.	Ankle brachial index	35
6.2.	<i>Diagnostic imaging</i>	35
6.3.	<i>Management</i>	35
6.3.1.	Time to repair	35
6.3.2.	Penetrating extremity vascular trauma	36
6.3.3.	Primary amputation	36
6.3.3.1.	<i>Decision support tools</i>	36
6.3.4.	Non-occlusive extremity vascular injuries	37
6.3.5.	Open or endovascular repair	37
6.3.6.	Arterial injuries below knee or elbow	37
6.3.7.	Intra-operative heparinisation	38
6.3.8.	Extremity venous injuries	38
6.3.9.	Compartment syndrome and fasciotomy	39
6.4.	<i>Post-operative surveillance in extremity vascular trauma</i>	39
7.	<b>Post-operative general considerations after vascular trauma</b>	40
7.1.	<i>Post-operative surveillance</i>	40
7.2.	<i>Antibiotic prophylaxis after vascular trauma</i>	40
7.3.	<i>Post-operative antithrombotic therapy</i>	40
8.	<b>Paediatric vascular trauma</b>	41
8.1.	<i>General considerations</i>	41
8.2.	<i>Neck vessel injuries</i>	41
8.3.	<i>Thoracic aortic injury</i>	41
8.4.	<i>Abdominal vascular injuries</i>	42
8.5.	<i>Extremity vascular trauma</i>	42
8.6.	<i>Post-operative considerations</i>	42
9.	<b>Gaps in evidence and recommendations for future research</b>	43
10.	<b>Patients' perspectives</b>	43
10.1.	<i>Introduction</i>	43
10.2.	<i>Symptoms and diagnosis of vascular trauma</i>	44
10.3.	<i>How to stop severe bleeding?</i>	44
10.4.	<i>Management</i>	44
10.5.	<i>Follow up</i>	44
10.6.	<i>Outcome</i>	44
	Acknowledgements	45
	References	45

## ABBREVIATIONS AND ACRONYMS

AAST	The American Association for the Surgery of Trauma	MESS	Mangled Extremity Severity Score
ABI	Ankle brachial index	MESI	Mangled Extremity Syndrome Index
AGREE	Appraisal of Guidelines for Research and Evaluation	MRA	Magnetic resonance angiography
ATLS	Advanced Trauma Life Support	MRI	Magnetic resonance imaging
AVF	Arteriovenous fistula	OSR	Open surgical repair
AVI	Abdominal vascular injury	PTAI	Penetrating thoracic aortic injury
BCVI	Blunt cervical vascular injury	PV	Portal vein
BTAI	Blunt thoracic aortic injury	RCT	Randomised controlled trial
CCA	Common carotid artery	REBOA	Resuscitative endovascular balloon occlusion of aorta
CT	Computed tomography	SMA	Superior mesenteric artery
CTA	Computed tomography angiography	SMV	Superior mesenteric vein
DOAC	Direct oral anticoagulant	SVS	Society for Vascular Surgery
DSA	Digital subtraction angiography	TBI	Traumatic brain injury
DUS	Duplex ultrasound	TEVAR	Thoracic endovascular aortic repair
ESVS	European Society for Vascular Surgery		
FAST	Focused Assessment with Sonography in Trauma		
GWC	Guideline Writing Committee		
ICA	Internal carotid artery		
IVC	Inferior vena cava		
LMWH	Low molecular weight heparin		

## STUDY ACRONYMS

CADISS	Cervical Artery Dissection in Stroke Study
COMPASS	Cardiovascular Outcomes for People Using Anticoagulation Strategies
CRASH-2	Clinical Randomisation of an Antifibrinolytic in Significant Haemorrhage
PROOVIT	PROspective Observational Vascular Injury Trial

**Table 1. Summary table of recommendations.**

**Recommendations included in the European Society for Vascular Surgery (ESVS) 2025 clinical practice guidelines on the management of vascular trauma. Numbers correspond to the numbers of the recommendations in the guideline document.**

**Class I recommendations**

1. Rapid access to a 24/7 clinical team competent in haemorrhage control and delivery of both open and endovascular surgery is recommended for the management of patients with life or limb threatening vascular injuries
2. Implementation of civilian and military vascular trauma curricula and dedicated training are recommended for the development and maintenance of vascular trauma decision making and technical skills
3. Emergency access to an operating room with hybrid capability is recommended for the operative treatment of the trauma patient with a vascular injury
4. Damage control resuscitation principles and massive transfusion protocols used for patients with traumatic haemorrhage are recommended for patients with vascular trauma
5. Early administration of tranexamic acid is recommended for all severely bleeding patients with vascular trauma
6. A pre-hospital tourniquet, applied as distally as possible, is recommended for patients with uncontrolled bleeding from extremity vascular trauma when local compression and or packing are not sufficient
9. Haemodynamically unstable patients, deemed unsuitable for computed tomography angiography, are recommended to be immediately transferred to the operating room for surgical intervention
10. Computed tomography angiography, including arterial and venous phase, is recommended as the first line investigation to identify or rule out vascular injury in trauma patients without clinical signs of active bleeding
12. Restoration of inline arterial flow, temporarily or definitively, is recommended to be prioritised in the management of limb or end organ threatening vascular trauma
13. Primary definitive repair for patients with vascular trauma is recommended over temporary solutions
14. The use of temporary vascular shunts to rapidly restore blood flow is recommended when timely primary definitive vascular repair is not feasible due to patient physiology or injury pattern
16. Short interposition grafts are recommended in patients with vascular trauma requiring reconstruction
19. Immediate open surgical exploration is recommended for patients with penetrating neck injury and active haemorrhage from the wound or expanding haematoma
20. Computed tomography angiography is recommended for all patients with penetrating neck trauma without an indication for immediate operative intervention
22. Reconstruction rather than ligation of the common or internal carotid artery, when patient physiology allows and technically feasible, is recommended in patients with a penetrating ESVS Grade 2 or 3 carotid artery injury
25. Emergency endovascular management with embolisation if feasible, is recommended for patients with penetrating extracranial vertebral artery injury and uncontrolled haemorrhage (ESVS Grade 3)
27. Ligation is recommended if repair of internal jugular vein injury is not easily achievable, provided one internal jugular vein remains patent
29. Computed tomography angiography including intracerebral vessels is recommended for all patients at risk of blunt cerebrovascular injury
31. Non-operative management with single antiplatelet therapy is recommended for patients with blunt, low grade carotid artery injury (ESVS Grade 1)
34. Operative treatment with open repair or endovascular stent graft is recommended for patients with blunt carotid artery injury and active haemorrhage (ESVS Grade 3)
37. Management with antiplatelet therapy as first line treatment is recommended for patients with blunt vertebral artery injury without active haemorrhage (ESVS Grades 1, 2, or X)
38. Emergency endovascular management with embolisation, if feasible, is recommended for patients with blunt extracranial vertebral artery injury and uncontrolled haemorrhage (ESVS Grade 3)
40. Systolic blood pressure (90 – 110 mmHg) and heart rate (<100/minute) control are recommended for patients with untreated blunt thoracic aortic injury except in the presence of hypovolaemic shock or traumatic brain injury
41. Referral to a trauma centre with 24/7 multispecialty expertise to treat aortic pathology is recommended for all patients with blunt thoracic aortic injury
43. Computed tomography angiography of the aorta is recommended for the diagnosis and characterisation of blunt thoracic aortic injury
44. Non-operative management with blood pressure control and follow up imaging is recommended in patients with ESVS Grade 1 blunt thoracic aortic injury without concomitant severe traumatic brain injury
47. Urgent (< 24 hour) endovascular stent graft repair is recommended for patients with blunt thoracic aortic injury and any external contour abnormality (ESVS Grade 2) with high risk aortic features (see [Table 10](#))
48. Immediate operative repair is recommended for patients with blunt thoracic aortic injury with active extravasation (ESVS Grade 3)
52. Left subclavian artery revascularisation is recommended for selected patients with blunt thoracic aortic injury requiring endovascular stent graft repair with coverage of the left subclavian artery and risk of compromised perfusion to brain, heart, or spinal cord
54. Open surgical repair is recommended in selected patients with blunt thoracic aortic injury requiring intervention and with aortic anatomy unsuitable for a stent graft

*Continued*

Table 1-continued

55. Active distal aortic perfusion is recommended to minimise the risk of paraplegia for patients with blunt thoracic aortic injury undergoing open surgical repair
56. Follow up imaging is recommended for patients with blunt thoracic aortic injury who have undergone endovascular stent graft repair, at one month, one year, and thereafter continued for at least five years
57. Surveillance imaging, until aortic remodelling, is recommended for patients with blunt thoracic aortic injury who have not undergone thoracic aortic repair
58. Magnetic resonance angiography is recommended as the preferred imaging method for long term surveillance after blunt thoracic aortic injury
61. Immediate surgical exploration and haemorrhage control are recommended for patients in shock with ongoing bleeding and suspicion of major abdominal vascular injury
62. Surgical exploration of retroperitoneal haematomas during trauma laparotomy is recommended in patients who are haemodynamically unstable OR who have an unstable retroperitoneal haematoma (expanding, pulsatile, or actively bleeding)
63. A non-exploratory approach to retroperitoneal haematomas during trauma laparotomy, with subsequent computed tomography angiography imaging, is recommended for patients who are haemodynamically stable AND have a stable retroperitoneal haematoma (not expanding, not pulsatile, and not actively bleeding)
64. Non-operative management with surveillance and antithrombotic therapy is recommended for patients without ongoing bleeding and blunt minor abdominal aortic, iliac, renal, or superior mesenteric artery injuries (ESVS Grade 1) on computed tomography angiography
65. Open surgical repair is recommended as first line treatment for patients with a blunt or penetrating abdominal aortic injury with free haemorrhage and haemodynamic instability (ESVS Grade 3)
66. Synthetic graft material is recommended for aortic reconstruction in emergency situations with or without concomitant bowel injury
69. Primary surgical repair, synthetic interposition graft reconstruction, or vascular shunting is recommended for common or external iliac artery injury (ESVS Grade 3) discovered during emergency laparotomy
71. Endovascular treatment with embolisation is recommended for patients with pelvic injury and clinical signs of ongoing bleeding or imaging showing extravasation from the internal iliac artery or its branches
73. Ligation is recommended for treatment of inferior mesenteric artery injury
76. Ligation of the renal artery, with or without simultaneous nephrectomy, is recommended in a haemodynamically unstable patient with severe renal artery injury (ESVS Grade 3)
78. Open or endovascular renal artery repair is recommended for patients with bilateral ESVS Grade 2, 3, or X renal artery injuries or if there is a solitary salvageable kidney
79. Vein ligation is recommended for abdominal venous injury if repair is not easily achievable
82. Careful clinical vascular examination is recommended in all patients with extremity trauma to identify potential haemorrhagic or ischaemic vascular injuries
84. Immediate computed tomography angiography is recommended as the primary imaging modality in patients with extremity injury where significant vascular injury cannot be ruled out by clinical vascular examination (palpable peripheral pulses)
85. Revascularisation as soon as possible, ideally within one hour of admission, is recommended in patients with clinical evidence of acute ischaemia due to extremity vascular trauma
86. The use of a temporary vascular shunt to rapidly restore blood flow in the extremity is recommended when timely primary definitive vascular repair is not feasible due to patient physiology or skeletal instability
88. Multidisciplinary decision making regarding revascularisation vs. primary amputation is recommended in patients with complex extremity trauma
91. Endovascular embolisation is recommended for active bleeding from side branches of major arteries in patients with extremity injuries
92. If repair is not easily achievable, ligation is recommended in isolated radial or ulnar arterial injury without evidence of distal ischaemia
96. Emergency four compartment fasciotomy is recommended to treat traumatic post-ischaemic lower limb compartment syndrome
99. Computed tomography angiography is recommended as the first line investigation to identify or rule out vascular injury in haemodynamically stable paediatric trauma patients
100. Early antithrombotic therapy is recommended for children with blunt, low grade carotid artery injury (ESVS Grade 1 or 2)
102. Immediate surgical exploration and bleeding control are recommended for children in shock with ongoing haemorrhage and suspicion of major abdominal vascular injury
103. Clinical vascular examination in line with adult guidance is recommended in all children with upper or lower extremity trauma to identify potential haemorrhagic or ischaemic vascular injuries

**Class IIa recommendations**

15. Vascular shunts should be considered for conversion to definitive repair as soon as possible, ideally at the primary operation
18. Vein grafts should be considered for vascular reconstruction of arterial injuries requiring longer bypass conduits or for small calibre distal vessels
24. Endovascular therapy should be considered as first line treatment for symptomatic or progressing pseudoaneurysm or arteriovenous fistula (ESVS Grade 2) in patients with penetrating vertebral artery injury

*Continued*

Table 1-continued

26. Non-operative management with single antiplatelet therapy should be considered for patients with penetrating extracranial vertebral artery injury and occlusion (ESVS Grade X) without neurological symptoms
30. The use of screening protocols to identify cervical vascular injury early should be considered for patients with blunt trauma.
35. Non-operative management with single antiplatelet therapy should be considered for patients with blunt carotid injury and complete occlusion (ESVS Grade X) without neurological symptoms
36. Management of blunt carotid injury and complete occlusion (ESVS Grade X) with neurological symptoms should be considered on an individual basis, including the duration of neurological symptoms, risk of reperfusion injury, and signs of brain infarction on computed tomography.
39. Surveillance with computed tomography angiography at one week and three months should be considered for patients with blunt carotid artery injury (ESVS Grade 1 or 2) undergoing non-operative management with antiplatelet treatment
46. Delayed (> 24 hour) endovascular stent graft repair should be considered for patients with blunt thoracic aortic injury and any external wall contour abnormality (ESVS Grade 2) if there are no high risk injury features (see Table 10)
49. Intra-operative systemic heparinisation for thoracic aortic stent graft repair should be considered individualised, including the perceived risks of bleeding, thromboembolic complications, and severity of traumatic brain injury
50. Stent graft oversizing between 20% and 30%, depending on the hypovolaemic status during index computed tomography angiography, should be considered for patients with blunt thoracic aortic injury undergoing emergency endovascular treatment
53. Delayed left subclavian artery revascularisation should be considered for selected patients with blunt thoracic aortic injury requiring endovascular stent graft repair who develop ischaemic symptoms with coverage of the left subclavian artery
59. The treatment choice between open surgical and endovascular repair of innominate artery or proximal left common carotid artery injury (ESVS Grade 2 and 3) should be considered based on haemodynamic status, anatomy, and concomitant injuries
60. Endovascular stent graft repair should be considered the preferred treatment modality for patients with subclavian artery injury (ESVS Grade 2 and 3) requiring operative treatment
67. Endovascular stent graft repair should be considered for haemodynamically stable patients and abdominal aortic injury with external contour abnormality such as a pseudoaneurysm (ESVS Grade 2)
68. Stent graft oversizing between 20% and 30% should be considered when imaging was performed during hypotension for patients with an abdominal aortic injury undergoing emergency endovascular treatment
70. Endovascular stent graft repair should be considered for ESVS Grade 2 or 3 common or external iliac artery injury
75. Open or endovascular renal artery repair should be considered for haemodynamically stable patients and ESVS Grade 3 renal artery injury
77. Endovascular stent graft repair should be considered for haemodynamically stable patients with ESVS Grade 2 injury (e.g., pseudoaneurysm) of the renal artery
80. Non-operative management with close observation and follow up imaging should be considered in haemodynamically stable patients with an inferior vena cava injury and a stable retroperitoneal haematoma (not expanding and not actively bleeding)
95. Repair of localised femoral or popliteal venous injury should be considered over ligation in haemodynamically stable patients
101. Endovascular stent graft repair should be considered as the first line operative treatment for children with blunt thoracic aortic injury (ESVS Grade 2 or 3) and appropriate anatomy
104. Non-operative management should be considered in a child with a pink and warm, but pulseless, hand post-supracondylar humeral fracture reduction with close observation for the development of acute ischaemia

**Class IIb recommendations**

17. Synthetic interposition grafts may be considered for emergency definitive vascular repair
21. Non-operative management with single antiplatelet therapy may be considered for patients with minor (ESVS Grade 1) carotid artery injury due to penetrating trauma
23. Non-operative management with single antiplatelet therapy may be considered for patients with an ESVS Grade 1 vertebral artery injury due to penetrating trauma
33. Delayed endovascular treatment may be considered for patients with blunt carotid or vertebral artery injury and enlarging pseudoaneurysm (ESVS Grade 2) or neurological symptoms
45. Endovascular stent graft repair may be considered in patients with ESVS Grade 1 blunt thoracic aortic injury and concomitant severe traumatic brain injury when blood pressure control is not feasible
72. Endovascular stent or stent graft repair may be considered for ESVS Grade X superior mesenteric artery injury to achieve early restoration of bowel perfusion
89. Non-operative management with clinical and imaging follow up may be considered for patients with extremity non-occlusive vascular injuries (ESVS Grade 1 or 2)
90. Endovascular stent or stent graft repair may be considered as an alternative to open repair in selected patients with extremity vascular trauma requiring operative treatment (ESVS Grade 2, 3, or X)
93. Ligation or embolisation of an isolated infragenicular arterial injury without evidence of distal ischaemia may be considered in patients with one of the anterior or posterior tibial arteries intact and patent

*Continued*

Table 1-continued

94.	Intra-operative systemic heparinisation in patients with extremity trauma may be considered on an individual basis, including the extent of repair, duration of interrupted blood flow, concomitant injuries and overall risk of bleeding, and degree of trauma induced coagulopathy
97.	Post-operative follow up with clinical examination and duplex ultrasound one month after repair, or earlier if abnormal findings or symptoms develop, may be considered for patients with extremity vascular injury and vascular reconstruction
98.	Post-operative single antiplatelet therapy may be considered for patients with vascular trauma who have undergone open or endovascular repair
105.	Post-operative follow up with clinical examination and duplex ultrasound one month after repair, or earlier if abnormal findings or symptoms develop, may be considered for children with extremity vascular injury reconstructed with bypass or interposition graft
<b>Class IIIa recommendations</b>	
7.	Heparinisation is not indicated as part of tourniquet management in patients with uncontrolled bleeding from extremity vascular trauma
51.	Routine left subclavian artery revascularisation is not indicated for patients with blunt thoracic aortic injury requiring endovascular stent graft repair with coverage of the left subclavian artery
81.	Atriocaval shunting is not indicated in the management of inferior vena cava injuries
83.	An ankle brachial index is not indicated to diagnose or rule out vascular injury in patients with extremity trauma
<b>Class IIIb recommendations</b>	
8.	Resuscitative endovascular balloon occlusion of the aorta (REBOA) is not recommended as a routine approach for temporary haemorrhage control in trauma patients with exsanguinating torso haemorrhage
11.	Avoiding or postponing computed tomography angiography because of possible renal impairment is not recommended in haemodynamically stable patients with potentially life or limb threatening vascular injuries
28.	Clinical examination alone is not recommended to rule out cervical vascular injury in patients with blunt neck trauma
32.	The use of routine endovascular stenting as an adjunct to antithrombotic therapy is not recommended for patients with blunt carotid artery injury without active bleeding (ESVS Grade 1 or 2)
42.	Chest Xray is not recommended as an imaging technique to exclude blunt thoracic aortic injury
74.	Revascularisation of a devascularised unilateral kidney identified on computed tomography angiography is not recommended
87.	The use of scoring systems when deciding upon limb salvage or amputation for patients with extremity trauma is not recommended

ESVS = European Society for Vascular Surgery.

## 1. METHODOLOGY

### 1.1. Introduction

Trauma is a major global public health issue, and vascular trauma sits at the most extreme end of injury care.<sup>1</sup> Decisions and interventions for massive bleeding make the difference between life and death, while those for acute ischaemia will save limbs and avoid long term disability. The vascular trauma field has rapidly evolved over the last decades with improved resuscitation strategies, higher quality diagnostic testing, and evolving endovascular techniques.<sup>2</sup> A contributing factor to these changes has been the increased volume of patients with vascular injuries in civilian life and during military conflicts and terror attacks.<sup>3–5</sup> The management of vascular trauma is challenging and time critical. Decisions usually have to be made without the opportunity for planned multi-specialty discussions. It is therefore critical that clinicians are supported with clear, practical management approaches founded on the best available evidence.

The European Society for Vascular Surgery (ESVS) has therefore developed clinical practice guidelines for the care of patients with vascular trauma, with the aim of assisting physicians in selecting the optimal management strategy. The guidelines should under no circumstance be seen as the legal standard of care in all patients. The document provides guidance and support, but the care given to an individual patient is always dependent on a number of factors. The

primary target audience for these guidelines includes all clinicians who are directly involved in the management of vascular trauma, to include vascular and trauma surgeons and trainees in these disciplines, as well as anaesthetists, intensivists, diagnostic and interventional radiologists, emergency physicians, and plastic and orthopaedic surgeons. The guidelines were therefore developed by a multidisciplinary group of specialists in the trauma field to promote a high standard of care based on the highest quality evidence available. The recommendations represent the knowledge at the time of publication, but knowledge in this field may change rapidly; therefore, recommendations can become outdated. These guidelines are built on established principles of Advanced Trauma Life Support (ATLS) and damage control resuscitation and surgery.

### 1.2. Guideline Writing Committee

Members of the Guideline Writing Committee (GWC) were selected by the chairs and ESVS Guideline Steering Committee to represent European and US clinicians involved in vascular trauma management, including vascular and trauma surgeons, anaesthetists, and interventional radiologists.

Members of the GWC have provided disclosure statements regarding relationships that might be perceived as conflicts of interest. These are available from ESVS headquarters ([info@esvs.org](mailto:info@esvs.org)). Members of the GWC received no

financial support from any pharmaceutical, device, or industry body to develop these guidelines. There was no funding body that influenced the content of these guidelines.

The GWC held introductory meetings when topics and author tasks were determined, followed by a face to face meeting in Amsterdam on 25 – 26 May 2023. The GWC drafted a table of contents that was divided into distinct sections. Authors were chosen to co-lead the writing of each section. Vascular trainees were invited from across Europe to participate in evidence collation and systematic literature reviews.<sup>6</sup> The GWC met regularly by videoconference to discuss the writing process and ongoing issues. After the first draft was completed and internally reviewed, the GWC held a videoconference on 10 May 2024 to review and approve the wording and grading of each recommendation. Consensus recommendations were discussed and agreed during these meetings and had to have majority consensus from all members of the GWC to be included. A final GWC review and approval of the document were performed following changes made after peer review.

### 1.3. Literature search and selection

A systematic literature search for relevant papers published in English between 1 January 2000 and 31 December 2022 was performed using the databases MEDLINE (through PubMed), Embase, Cardiosource Clinical Trials Database, and Cochrane Library. This date range was chosen to ensure a contemporary view of vascular trauma while ensuring sufficient evidence would be included to provide meaningful recommendations. Literature searches were updated in February 2024. Relevant articles published after the search dates or in a language other than English were included, but only if they were of paramount importance to the guidelines. The search terms used for the different chapters and subsections are mentioned in [Appendix A](#). Selection of the literature was performed following the pyramid of evidence, with aggregated evidence at the top of the pyramid (systematic reviews, meta-analyses), then randomised controlled trials (RCTs), then observational studies. Single case reports, animal studies, and *in vitro* studies at the bottom of the pyramid were excluded.

### 1.4. Evidence and recommendation grading criteria

The ESVS clinical practice guidelines recommendation grading system was used for grading the level of evidence and class of recommendations.<sup>7</sup> For each recommendation made in the guideline, the level of evidence was graded from A to C ([Table 2](#)), with A being the highest. The strength (class) of each recommendation was graded from I to III, with class I being the strongest ([Table 3](#)). Expanded information from the studies used for each recommendation is shown in the tables of evidence ([ToE](#)).

Appraisal of Guidelines for Research and Evaluation (AGREE) II reporting standards for assessing the quality and reporting of practice guidelines were adopted during preparation of the guidelines, and a checklist (AGREE II checklist) is available in [Appendix A](#).<sup>8</sup>

**Table 2. European Society for Vascular Surgery (ESVS) clinical practice guidelines levels of evidence grading system.**

Level of evidence A	Data derived from multiple randomised trials or meta-analyses of randomised trials
Level of evidence B	Data derived from a single randomised trial, high quality non-randomised studies, or a meta-analysis of such studies
Level of evidence C	Data derived from consensus opinion of experts, from low quality <sup>*</sup> studies, or meta-analysis of such studies

\* Large prospective, population based, observational, or registry studies.

\*\* Small retrospective studies or case series.

### 1.5. Review process

The guideline document underwent a formal external expert peer review process and, additionally, was reviewed and approved by the ESVS Guideline Steering Committee. The guidelines and the app can be downloaded from the ESVS website (<https://www.esvs.org/journal/guidelines/>).

The 2025 ESVS clinical practice guidelines on the management of vascular trauma are expected to be updated within a five year period.

### 1.6. Limitations

These guidelines have important limitations affecting generalisability. There is a general paucity of high quality data and literature on vascular trauma management. This applies to aspects relating to sex and ethnicity, but also conditions of low and medium income countries. These limitations must be kept in mind when managing vascular trauma in different settings and environments.

Some topics were deemed to be beyond the scope of these guidelines, such as iatrogenic vascular injuries,

**Table 3. European Society for Vascular Surgery (ESVS) clinical practice guidelines class of recommendation grading system.**

Class	Definition	Wording
I	Evidence and or general agreement that a given treatment or procedure is beneficial, useful, effective	is or are recommended
II	Conflicting evidence and or divergence of opinion about the usefulness or effectiveness of the given treatment or procedure	
IIa	Weight of evidence or opinion is in favour of usefulness or effectiveness	should be considered
IIb	Usefulness or effectiveness is less well established by evidence or opinion	may be considered
III	Evidence or general agreement that a given treatment or procedure is not useful or effective, and in some cases may be harmful	
IIIa	The given treatment or procedure is not necessarily useful or effective	is or are not indicated
IIIb	The given treatment or procedure may be dangerous or harmful to patients	is or are not recommended



although many of the described management principles can be applied in these situations. There was no formal evaluation of facilitators and barriers, and the guidelines did not have the scope to go into detail regarding health economics.

## 2. VASCULAR TRAUMA GENERAL CONSIDERATIONS

### 2.1. Vascular trauma epidemiology

Vascular trauma is a significant cause of morbidity and mortality worldwide.<sup>4,9</sup> The epidemiology of vascular trauma varies depending on the population studied, the mechanism and severity of injury, and the nature of the healthcare environment (e.g., urban, rural, military, or humanitarian situations).<sup>1,10–12</sup>

Available epidemiological data come mainly from countries with large population based trauma registries, including the USA, Germany, Sweden, Australia, and the UK.<sup>13–16</sup> Vascular injuries account for approximately 2 – 5% of all trauma admissions.<sup>14,17</sup> In the setting of a major European trauma centre, vascular injuries were present in 4.4% of total trauma admissions.<sup>9</sup> The incidence of vascular trauma is highest among young males and is substantially lower in older patients (0.7% for patients aged  $\geq 65$  years vs. 2.0% incidence in younger adults).<sup>14</sup> Geriatric patients who sustain a vascular injury are, however, often more severely injured and are more likely to have sustained a blunt traumatic vascular injury than their younger adult counterparts. Vascular trauma in the paediatric population is also less common, occurring in 0.6% of all paediatric trauma patients.<sup>13</sup>

Penetrating injuries are the most common cause of vascular trauma in urban areas, with a large variation across or within countries.<sup>4,12,17–19</sup> Firearm injuries in particular carry a highly vascular trauma burden, with up to 16% of gunshot patients having at least one vascular injury.<sup>19</sup> Firearm injuries requiring vascular repair also have higher injury severity and subsequent mortality rate than injuries with no need for vascular repair.<sup>4</sup> Blunt trauma is predominant in rural areas, from mechanisms such as motor vehicle collisions, falls, and industrial accidents. Compared with penetrating vascular trauma, patients with blunt trauma are in general more severely injured and have higher mortality and higher limb amputation rates.<sup>9</sup>

The anatomic distribution of civilian vascular injury in large registry data includes the extremities in 44% (upper extremity 26%, lower extremity 18%), followed by the torso (abdomen 25%, chest 24%), and the neck 10%.<sup>2,14</sup> Penetrating trauma patients who survive to reach hospital have more extremity and junctional vascular injuries (junction of the torso to the extremities, neck, and the perineal region), whilst central vascular injuries are more common following blunt trauma.<sup>9</sup>

From a mechanistic perspective, knife or gunshot wounds may cause a direct partial or complete transection of the vessel. Fractured bone can also directly lacerate vessels. High velocity gunshot wounds can cause indirect damage to arteries near the bullet track owing to indirect energy transfer. Blunt trauma may cause vascular injury by stretching or impingement of the vessel wall with an intimal

**Table 4. Orthopaedic injuries associated with vascular injuries.**

Orthopaedic injury	Vascular injury
Distal femur fracture	Superficial femoral artery
Posterior knee dislocation	Popliteal artery
Proximal tibia fracture	Popliteal artery and trifurcation
Clavicle fracture	Subclavian artery
Shoulder dislocation	Axillary artery
Supracondylar humerus fracture	Brachial artery
Elbow dislocation	Brachial artery
Cervical spine injury	Carotid and or vertebral artery
Pelvic fracture	Internal iliac artery branches

tear and subsequent thrombus formation. Examples of orthopaedic injuries associated with vascular injuries are provided in Table 4, which also emphasise the importance of the clinical vascular examination before and after fracture reduction. In the thorax, blunt aortic injury can be caused by deceleration forces leading to shearing in the region of the isthmus, while in the abdomen, lap seat belt straps may cause direct injury to the aorta.

Vascular injury is a leading cause of death and disability in conflicts.<sup>11,20–23</sup> Up to 18% of patients who sustained a battle related injury had vascular injuries, averaging nearly two vascular injuries per patient.<sup>21</sup> Extremity trauma dominated, followed by torso and cervical injuries.<sup>21</sup> In terror related civilian trauma, vascular injury rates can approach 30%, depending on the type of attack.<sup>5,24</sup> Blast injuries, such as those caused by improvised explosive devices, can lead to complex injury patterns with substantial vascular components.<sup>25</sup>

### 2.2. General principles for vascular trauma care

Trauma care needs to be organised to ensure that major trauma patients receive high quality care at the most appropriate hospital across the trauma system. Regional trauma centralisation and referral to trauma centres have improved trauma care and outcomes, with a reduction in the mortality rate of severely injured trauma patients.<sup>26,27</sup> These trauma centres have an important role in local trauma system development, regional disaster planning, and advancing trauma care through research and use of trauma registries.<sup>28</sup> Several trauma systems have been described, and the optimal organisation of trauma care hospitals may differ between regions and countries.<sup>29</sup>

Established principles of trauma care management to identify life threatening conditions include the primary survey (ABCDE – airway, breathing, circulation, disability, exposure) and secondary survey standardised approach for rapid initial evaluation of the injured patient.<sup>30</sup> There is literature to support prioritising circulation during the primary survey in patients with an exsanguinating injury.<sup>31</sup> To emphasise the importance of rapid bleeding control during the primary patient assessment, an additional initial letter for the mnemonic C-ABCDE, standing for catastrophic haemorrhage control, has been widely adopted.<sup>32,33</sup> Damage control principles of resuscitation and surgery apply to the

vascular trauma patient.<sup>34,35</sup> Patients who are thought to be actively bleeding should be taken immediately to the operating room for emergency exploration.<sup>36</sup> Patients who do not require immediate haemorrhage control will usually undergo further diagnostic imaging.

### 2.3. Who should perform vascular trauma surgery?

Specific skill sets are required for the effective operative and peri-operative management of life or limb threatening vascular injuries.<sup>37</sup> When intervention is required, it has to be performed decisively and accurately, often out of working hours. Training and experience in open vascular and endovascular procedures varies across Europe and worldwide. While there is a growing consensus that surgeons without vascular residency or fellowship (or equivalent) should play a diminished role in vascular injury management, relatively few vascular surgeons have the experience to deliver acute vascular trauma care.<sup>38,39</sup> Emergency general surgeons have increasingly limited open vascular training and exposure, making it difficult to achieve and maintain competence.<sup>40–42</sup> Despite these challenges, workforce and training solutions must be found for all environments.<sup>43</sup>

Trauma general surgeons in high volume centres should be capable of managing most penetrating injuries requiring open vascular surgery, although infrapopliteal injuries tend to remain the province of vascular surgeons. Emergency and general surgeons are much less likely to have endovascular skills, which may reduce treatment options and innovation. In paediatric vascular trauma, expertise is much rarer and combined specialty input is often required.

While vascular trained trauma surgeons do exist in pockets across Europe, for most centres a multidisciplinary team of general surgery, vascular surgery, and interventional radiology clinicians will be required to ensure the best, most appropriate interventions can always be delivered.

Military environments have a high prevalence of vascular injuries, and vascular injury is a common cause for forward surgical intervention. However, there is limited access to vascular or endovascular specialists in these environments, and deployed personnel may have little recent experience of these injuries.

Recommendation 1			
Rapid access to a clinical team 24/7 competent in haemorrhage control and delivery of both open and endovascular surgery is recommended for the management of patients with life or limb threatening vascular injuries.			
Class	Level	References	ToE
I	C	DuBose <i>et al.</i> (2020), <sup>37</sup> Harfouche <i>et al.</i> (2022) <sup>39</sup>	

### 2.4. What technical skill set is required for vascular trauma surgery?

Effective delivery of vascular trauma surgery requires a broad skill set not found within a single standard surgical

specialty. Decision making, exposures, and techniques for vascular injuries are different from elective and emergency non-trauma vascular surgery. Surgeons must be able to rapidly expose and control all major arterial and venous structures in the chest, abdomen, pelvis, neck, and upper and lower limbs. Damage control operative techniques include thrombectomy, primary repair, shunting, ligation, fasciotomy, and amputation.<sup>22</sup> Additional definitive repair procedures include endovascular interventions, vascular anastomosis, and graft interposition.

Extremity trauma is the most aligned to other routine emergency and elective vascular procedures, although there are key differences in decision making, approaches, and procedures.<sup>44</sup> Vascular access and repair for torso trauma may require a multidisciplinary approach including other specialties (transplant, hepatobiliary, thoracic), although again there are key differences that must be understood.

Development and maintenance of this skill set in a single surgeon is difficult outside of high volume trauma centres with substantial operative workloads. Importantly, surgeons must also develop comfort in procedures that start with a field full of blood in an actively bleeding and decompensating patient. Courses in vascular access and control using simulation, cadaveric, and animal models can be valuable in developing and maintaining these skills. Trauma surgery involves more complex multiprofessional teams than other vascular emergencies and it is critical that surgeons understand and are comfortable working within these environments. Interdisciplinary and interprofessional trauma team training, to enhance leadership, teamwork, and communication, is vitally important to ensure successful outcomes. Ultimately there may be no substitute for dedicated time training in a high volume trauma centre, maintained through repeated visits throughout a civilian or military career.

#### Recommendation 2

Implementation of civilian and military vascular trauma curricula and dedicated training are recommended for the development and maintenance of vascular trauma decision making and technical skills.

Class	Level	References
I	C	Consensus

### 2.5. When are endovascular therapies required for vascular trauma?

Endovascular procedures are increasingly used for trauma care in up to 25% of patients with acute vascular and associated injuries, although this remains largely for patients who are haemodynamically stable.<sup>38,45</sup>

The most common endovascular procedures are embolisation of actively bleeding vessels, especially in anatomically challenging regions with difficult surgical access including the pelvis, chest wall, and deep vessels of

the buttock and extremity, as well as in the management of solid organ injury in haemodynamically stable patients.<sup>2,46–48</sup>

Blunt traumatic aortic injury is where endovascular stent graft repair has clear procedural and outcomes benefits over open surgery.<sup>46,49</sup> For other vessel injuries, there are multiple case reports and series in the literature of endovascular treatments for arterial and some venous injuries.<sup>50–52</sup> There has been a rise in the use of endovascular techniques for trauma management as familiarity, expertise, and availability have increased. However, these remain less established with a low evidence base. The most effective applications appear to be in areas with challenging open surgical access, such as thoracic aorta and subclavian artery injuries, where endovascular techniques can facilitate a hybrid approach with proximal control, or definitive stent graft (covered stent) repair.<sup>2,53,54</sup> Using stent grafts to manage other peripheral arterial injuries may not adequately address the local injury in terms of debridement and concomitant vein or nerve injuries. These approaches may have a role in staged haemorrhage control as part of damage control procedures. There are issues of long term patency and durability, in a population that is difficult to follow up.

Emergency hybrid operating rooms suitable for trauma care are evolving and experience is growing.<sup>55,56</sup> They allow multimodal approaches to difficult vascular access and haemorrhage control. Hybrid approaches facilitated by these rooms may reduce time to resuscitation and definitive vascular control when appropriately located and resourced. It is likely that the full potential for endovascular or hybrid management of vascular injuries has not yet been realised.

#### Recommendation 3

Emergency access to an operating room with hybrid capability is recommended for the operative treatment of the trauma patient with a vascular injury.

Class	Level	References
I	C	Consensus

### 2.6. What approach to resuscitation should be used for vascular trauma?

The management of bleeding trauma patients has been the subject of intense research, and current guidelines focus on volume resuscitation with whole blood or equivalent ratios of balanced blood components. Modern damage control resuscitation paradigms for actively bleeding patients target the prevention, identification, and treatment of coagulopathy and pathophysiological changes associated with severe ischaemia and massive transfusion.<sup>32,57–59</sup> These damage control resuscitation principles integrate permissive hypotension, haemostatic resuscitation, and damage control surgery. No resuscitation research was found that focused specifically on the management of patients with vascular injury, as compared with other sources of bleeding.<sup>60</sup> In particular, no evidence was found to suggest different

approaches to the administration of the antifibrinolytic agent tranexamic acid for patients with vascular injury.<sup>61–63</sup> The CRASH-2 trial (Clinical Randomisation of an Anti-fibrinolytic in Significant Haemorrhage) ( $n = 20\,211$  adult trauma patients) undertaken in 274 hospitals in 40 countries, randomly assigned patients with, or at risk of, significant bleeding to either tranexamic acid (loading dose 1g over ten minutes then infusion of 1g over eight hours) or matching placebo.<sup>64</sup> All cause death was significantly reduced with tranexamic acid (1463 [14.5%] tranexamic acid group vs. 1613 [16.0%] placebo group; relative risk 0.91, 95% confidence interval [CI] 0.85 – 0.97). The risk of death due to bleeding was significantly reduced (489 [4.9%] vs. 574 [5.7%]; relative risk 0.85, 95% CI 0.76 – 0.96). A systematic review including seven RCTs found no compelling evidence of increased vascular occlusive events after tranexamic acid administration (odds ratio [OR] 0.96, 95% CI 0.73 – 1.27).<sup>65</sup> A recent registry (PROspective Observational Vascular Injury Treatment [PROOVIT] registry) study showed that tranexamic acid was not associated with a higher risk of thrombosis related technical failure in traumatic injuries requiring major vascular repairs.<sup>66</sup>

In summary, tranexamic acid should be administered early for all severely bleeding patients with vascular trauma, and the dosage should follow standard national and international guidelines for the management of trauma patients based on existing RCT (CRASH-2 trial).<sup>64,67,68</sup>

#### Recommendation 4

Damage control resuscitation principles and massive transfusion protocols used for patients with traumatic haemorrhage are recommended for patients with vascular trauma.

Class	Level	References	ToE
I	A	Holcomb <i>et al.</i> (2015), <sup>58</sup> Roberts <i>et al.</i> (2011), <sup>64</sup> Sperry <i>et al.</i> (2018) <sup>59</sup>	

#### Recommendation 5

Early administration of tranexamic acid is recommended for all severely bleeding patients with vascular trauma.

Class	Level	References	ToE
I	A	Roberts <i>et al.</i> (2011), <sup>64</sup> Fouche <i>et al.</i> (2024), <sup>65</sup> Asaadi <i>et al.</i> (2024) <sup>66</sup>	

### 2.7. Use of tourniquets for temporary bleeding control

Most bleeding from extremity vascular injuries can be controlled with direct pressure, which remains the immediate mainstay of treatment. However, a small number of injuries cannot be effectively controlled by local compression and or packing, or the nature of the environment precludes this. In these circumstances, pre-hospital application of a tourniquet has been shown to improve haemorrhage control and to reduce transfusion requirements

in both military and civilian settings.<sup>69–73</sup> Although no RCTs have been performed, results from prospective and retrospective studies are consistent. Pre-hospital application of a tourniquet, preferably before the onset of shock, as distal as possible may prevent exsanguination and save lives, with the risk of reported complications being low.<sup>74–76</sup> Tourniquets, with the time of application registered, should be checked frequently to see if they are still required, and removed as soon as possible under controlled conditions. Reassessment of the tourniquet for proper placement or conversion to haemostatic or pressure bandage is especially important when evacuation is prolonged.<sup>77</sup> After tourniquet removal, the patient needs to be assessed for rebleeding as well as reperfusion effects with compartment syndrome associated with prolonged ischaemia. Heparinisation is not indicated specifically because a tourniquet has been used, and there is no evidence to support this practice.

Recommendation 6			
A pre-hospital tourniquet, applied as distally as possible, is recommended for patients with uncontrolled bleeding from extremity vascular trauma when local compression and or packing are not sufficient.			
Class	Level	References	ToE
I	C	Scerbo <i>et al.</i> (2017), <sup>69</sup> Beekley <i>et al.</i> (2008), <sup>70</sup> Covey <i>et al.</i> (2022), <sup>71</sup> Benítez <i>et al.</i> (2021), <sup>72</sup> Henry <i>et al.</i> (2021), <sup>74</sup> Teixera <i>et al.</i> (2018) <sup>73</sup>	

Recommendation 7			
Heparinisation is not indicated as part of tourniquet management in patients with uncontrolled bleeding from extremity vascular trauma.			
Class	Level	References	ToE
IIIa	C	Consensus	

### 2.8. Resuscitative endovascular balloon occlusion of the aorta

Uncontrolled bleeding from non-compressible torso trauma carries a very high mortality rate.<sup>78</sup> Resuscitative endovascular balloon occlusion of the aorta (REBOA) is a technique that has been investigated to achieve temporary haemorrhage control prior to definitive surgery. REBOA involves placement of an endovascular balloon in the aorta to temporarily obtain proximal control of non-compressible torso haemorrhage as a bridge to definitive haemorrhage control. The use of REBOA should not delay definitive haemorrhage control.<sup>79</sup> Patient selection identifying which patients may benefit from REBOA remains challenging. A systematic review identified that variability existed in the specific systolic blood pressure trigger used, proactive femoral access, and its use in chest trauma and traumatic

cardiac arrest.<sup>80</sup> Data from observational and non-randomised studies of REBOA are conflicting with a risk of bias.<sup>79</sup> In a recent RCT, a strategy of in hospital REBOA plus standard care in the emergency department did not reduce, and may even increase, mortality compared with standard care alone.<sup>81</sup> At 90 days, 54% of patients (25/46) in the REBOA group had experienced all cause death vs. 42% of patients (18/43) in the standard care group (OR 1.58; [95% credible interval, 0.72 – 3.52]; posterior probability of an OR >1 [indicating increased odds of death with REBOA], 86.9%). The incidence of vascular complications of REBOA use has been estimated at 8% (95% CI 5 – 13%).<sup>82,83</sup> Several factors regarding REBOA, including indications, aortic occlusion time, devices used, training, and credentialing, require further analysis.<sup>84,85</sup>

Recommendation 8			
Resuscitative endovascular balloon occlusion of the aorta (REBOA) is not recommended as a routine approach for temporary haemorrhage control in trauma patients with exsanguinating torso haemorrhage.			
Class	Level	References	ToE
IIIb	B	Jansen <i>et al.</i> (2023) <sup>81</sup> , Maiga <i>et al.</i> (2022) <sup>80</sup>	

### 2.9. What diagnostic imaging should be used for emergency diagnosis of vascular trauma?

Computed tomography angiography (CTA) has sensitivity and specificity approaching 100% for the identification of clinically significant vascular injury.<sup>86–97</sup> CTA is established as the first line investigation in haemodynamically stable trauma patients whose outcome would not be impacted by the delay associated with this imaging method.<sup>95,98</sup> It is also the preferred post-operative imaging method to further analyse the vasculature when the patient has reached haemodynamic stability. While there are few comparative studies and some bias, modern CTA, including proper arterial and venous phases, performs as well as or better than conventional angiography across all types of vascular injury.<sup>92,95</sup> CTA may be oversensitive in the detection of injuries that are not clinically relevant, and findings must always be interpreted in line with the clinical status of the patient.<sup>94,99</sup> While intravenous contrast carries potential risks including contrast nephropathy, overall the risk of acute kidney injury following intravenous contrast use is very low.<sup>100</sup> In patients with potential life or limb threatening vascular injuries, it is therefore appropriate to proceed with CTA regardless of the patient's renal function.

Ultrasound investigations have been investigated for the diagnosis of vascular injury. Focused Assessment with Sonography in Trauma (FAST) is useful in haemodynamically unstable patients to identify free peritoneal, pleural, or pericardial blood.<sup>95,101</sup> The technology is commonly available, can be performed and easily repeated during resuscitation, and does not expose patients or staff to radiation.<sup>101</sup> While reasonably sensitive and specific for

clinically relevant haemorrhage, FAST does not identify the site of torso vascular injury and may miss major retroperitoneal vascular trauma.<sup>95</sup> In abdominal vascular injury, the diagnostic sensitivity has been shown to be as low as 41% when FAST is performed for blunt trauma in the absence of hypovolaemic shock, and a specificity as low as 18% in patients with gunshot wounds. Operator dependence may represent a limitation, with a missed injury rate approaching 10%, including major vascular injuries.<sup>102,103</sup>

Duplex ultrasound (DUS) has been used in the diagnosis of extremity and neck trauma, but there are few high quality studies on diagnostic test accuracy.<sup>104</sup> Duplex studies by a trained vascular sonographer are not commonly available within the required timeframe for the emergency evaluation of vascular injuries.

Digital subtraction angiography (DSA) has been replaced by CTA for most diagnostic requirements, as DSA is invasive, less available, and has a substantially longer acquisition time in most institutions.<sup>105</sup> On table DSA may have a role as a diagnostic modality in some patients rapidly transferred to the operating room for the management of other life threatening injuries. DSA may also complement CTA where there is doubt about the clinical significance of CTA findings (artefacts from metallic fragments or bullets, or below knee or elbow), as part of subsequent therapeutic intervention (e.g., DSA guided embolisation or proximal balloon control of arterial injury).

#### Recommendation 9

Haemodynamically unstable patients, deemed unsuitable for computed tomography angiography, are recommended to be immediately transferred to the operating room for surgical intervention.

Class	Level	References
I	C	Consensus

#### Recommendation 10

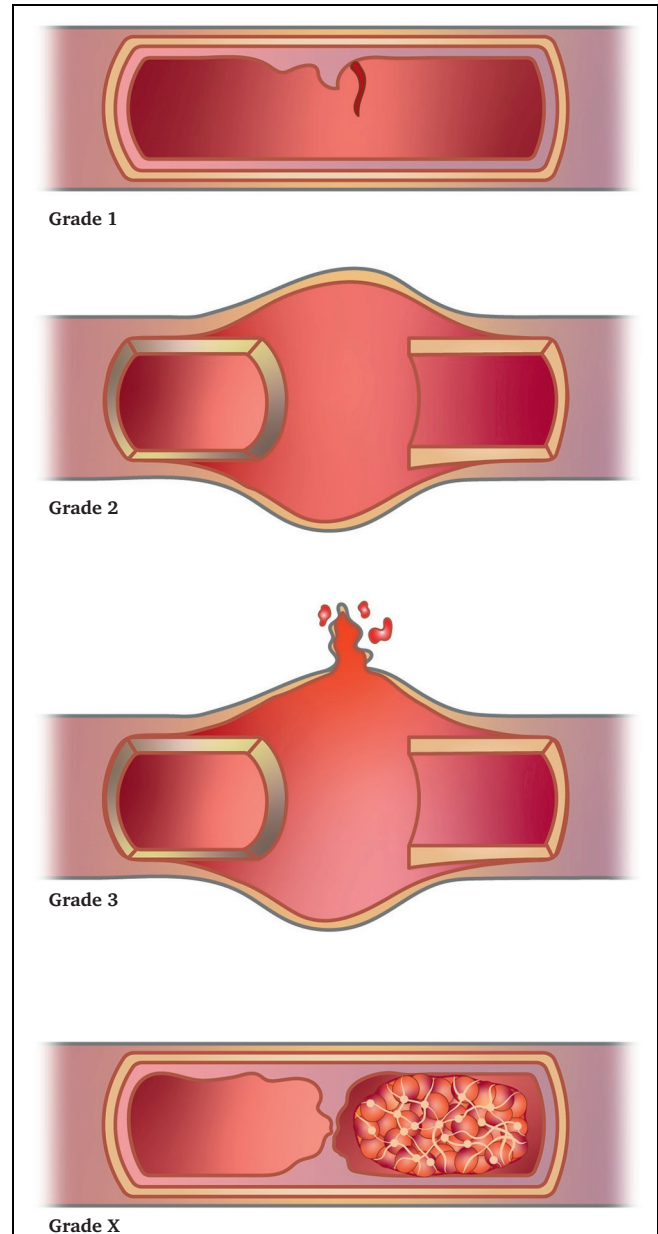
Computed tomography angiography, including arterial and venous phase, is recommended as the first line investigation to identify or rule out vascular injury in trauma patients without clinical signs of active bleeding.

Class	Level	References	ToE
I	C	Inaba <i>et al.</i> (2006), <sup>92</sup> Patterson <i>et al.</i> (2012), <sup>95</sup> Walkoff <i>et al.</i> (2021) <sup>98</sup>	

#### Recommendation 11

Avoiding or postponing computed tomography angiography because of possible renal impairment is not recommended in haemodynamically stable patients with potentially life or limb threatening vascular injuries.

Class	Level	References
IIIb	C	Consensus



**Figure 1.** European Society for Vascular Surgery (ESVS) grading system for arterial trauma: Grade 1, injury confined to the intima or vessel wall with normal external wall contour; Grade 2, external wall disruption with contained haemorrhage (e.g., pseudoaneurysm); Grade 3, complete wall transection with free rupture; and Grade X, vessel occlusion.

#### 2.10. European Society for Vascular Surgery grading system for arterial trauma

Throughout these guidelines, a new arterial injury grading system has been used to provide a framework for approaching the management of injuries (Fig. 1). This system is based on previous grading systems for individual arteries (e.g., Society for Vascular Surgery [SVS] thoracic aorta injury grades) and modified to reflect contemporary treatment decisions and pathways.

Table 5 shows the overall framework for the ESVS grading system and a general approach to management indicated by each grade. The ESVS Grades are 1 – 3 and X, with Grades 1 – 3

**Table 5. European Society for Vascular Surgery (ESVS) grading system for arterial trauma and management.**

ESVS Grade	Description	Examples	General management
1	Partial wall injury Normal external wall contour	Intimal flap Intramural haematoma	Observation ± antithrombotics
2	Complete wall injury Abnormal external wall contour Contained bleeding	Pseudoaneurysm Arteriovenous fistula	Urgent repair
3	Complete wall injury Uncontained haemorrhage	Blunt arterial transection Penetrating arterial injury	Emergency repair
X	Occlusion	Traction injury Transection	Emergency intervention if acutely ischaemic limb or end organ is salvageable

representing increasing severity of arterial wall disruption and risk of haemorrhage, and Grade X representing vascular occlusion with distal ischaemia. There are some differences related to individual body regions and arteries, and these are presented within the text for each section of these guidelines.

**ESVS Grade 1 injuries** are partial injuries to the internal vessel wall without compromise of the integrity of the vessel. This is represented as a normal, smooth external wall contour on CTA. Examples of such injuries are intimal flaps or intramural haematomas following blunt or traction injuries. There is no compromise to distal flow or end organ perfusion. ESVS Grade 1 injuries are usually managed non-operatively with clinical observation, often supplemented with surveillance imaging. In some Grade 1 injuries, antithrombotic therapy is indicated, detailed within the relevant sections of these guidelines.

**ESVS Grade 2 injuries** have complete disruption of the vessel wall but there is no external bleeding, or any bleeding is contained. There may be adventitial disruption leading to external bulging of the vessel wall (e.g., in blunt arterial injury) or contained bleeding such as a pseudoaneurysm or arteriovenous fistula (e.g., after penetrating vascular injury). ESVS Grade 2 injuries will usually require repair, and endovascular approaches are most commonly applicable.

**ESVS Grade 3 injuries** have complete disruption of the vessel wall with active, uncontained haemorrhage. Bleeding may be external or free into the thoracic or abdominal cavity. Patients are in haemorrhagic shock and dependent on volume transfusions. ESVS Grade 3 injuries require emergency repair, and this will usually be open surgery unless there is rapidly available access to endovascular methods and hybrid operating rooms.

**ESVS Grade X injuries** are occlusive and there is no flow beyond the injury. Common examples of these are traction injuries such as popliteal artery injury after knee dislocation or

renal artery injury after sudden deceleration. Grade X occlusive injuries may also represent complete transections where arterial spasm has contained the bleeding and allowed thrombus to form, or they may have started as intimal tears that have subsequently thrombosed the vessel lumen. Treatment of ESVS Grade X injuries is emergency intervention to restore flow provided the acutely ischaemic limb or end organ (e.g., kidney, brain) is salvageable.

### 2.11. How should perfusion be quickly restored in vascular trauma?

Loss of arterial blood flow to the limb will rapidly result in neural and muscular ischaemia resulting in pain, loss of function, necrosis, and amputation.<sup>106</sup> Delays to restoration of inline arterial flow result in unacceptably high rates of vascular trauma related limb loss. Functional loss begins within two to three hours of limb injury, and much of this time passes in the pre-hospital and pre-operative phases of care. Also, loss of arterial blood flow in the abdomen or neck may cause end organ ischaemia resulting in death or stroke. It is therefore imperative that arterial flow is restored as quickly as possible in the operating room.<sup>107,108</sup> Arterial flow may be restored definitively (primary repair, direct repair, or end to end anastomosis; graft reconstruction) or temporarily with shunts.<sup>109,110</sup> Which technique is used depends on the injury complexity, time since injury, and haemodynamic status of the patient.

#### Recommendation 12

**Restoration of inline arterial flow, temporarily or definitively, is recommended to be prioritised in the management of limb or end organ threatening vascular trauma.**

Class	Level	References	ToE
I	C	Alarhayem <i>et al.</i> (2019), <sup>107</sup> Vuoncino <i>et al.</i> (2023) <sup>108</sup>	

### 2.12. Vascular shunts vs. definitive repair

The use of temporary vascular shunts is well described as part of damage control trauma surgery as well as restoring arterial inflow and, if needed, venous outflow before orthopaedic fixation or vein harvest for reconstruction.<sup>111–113</sup> Shunt use is reported across military and civilian populations, and has been used in paediatric populations.<sup>114,115</sup> Shunts should be as short as possible, with a diameter maximised to increase flow but not so large that they damage vessel intima. Vascular shunts can be constructed from a sterile plastic tube, e.g., nasogastric tube or small chest drain, provided that the dimension of the tube reasonably corresponds to the inner diameter of the vessel. Also, commercially available carotid vascular shunts can be used. There are no strong data to recommend commercial shunts over improvised shunts.<sup>116</sup>

There is no high level evidence to support vascular shunt use, with most evidence coming from retrospective cohort data, most commonly comparing shunting with ligation.<sup>109,117,118</sup> Shunts placed in venous injuries may provide drainage and reduce venous hypertension, but short and long term patency rates are unknown and there is no evidence of improved limb

outcomes.<sup>119,120</sup> The Belfast experience (1979 – 2000) showed that early shunting of both artery and vein in penetrating and blunt injuries reduced the need for fasciotomy and amputations compared with the pre-shunt period.<sup>121</sup>

Most national trauma and vascular registries do not capture shunt use. While intuitively they allow faster restoration of flow, this may not be a clinically meaningful time improvement compared with other reconstructive options. It is of importance to control inflow and backflow of the injured vessel and to consider distal thrombectomy before shunt insertion. Shunt complications (e.g., occlusion, dislodgement, and embolisation) have been reported to occur in up to 20% of cases, and placement of a vascular shunt may alter subsequent repair options.<sup>23,122</sup> There is no consensus surrounding the factors associated with shunt thrombosis, although shunt sizing and vessel calibre have been implicated.<sup>120</sup> Any benefit of routine post-operative heparinisation has not been demonstrated.

Where possible, rapid definitive repair is the preferred option. Shunts may be particularly useful where there is limited vascular expertise to perform reconstruction and where patients have multiple critical injuries that must be dealt with simultaneously.

Recommendation 13			
Primary definitive repair for patients with vascular trauma is recommended over temporary solutions.			
Class	Level	References	ToE
I	C	Consensus	

Recommendation 14			
The use of temporary vascular shunts to rapidly restore blood flow is recommended when timely primary definitive vascular repair is not feasible due to patient physiology or injury pattern.			
Class	Level	References	ToE
I	C	Tung <i>et al.</i> (2021), <sup>111</sup> Borut <i>et al.</i> (2010), <sup>112</sup> Subramanian <i>et al.</i> (2008), <sup>113</sup> Polcz <i>et al.</i> (2021), <sup>117</sup> Laverty <i>et al.</i> (2022), <sup>118</sup> Feliciano <i>et al.</i> (2013) <sup>109</sup>	

The duration of shunting is not consistently reported in the literature, and there is little high quality evidence on timing of removal and definitive repair. Better patency rates are seen in proximal vessel injuries where there are higher flows. Experimental and limited human data suggest that complication rates increase after six hours.<sup>123</sup> Few complex trauma patients will be taken back within six hours of injury given the time required for critical care stabilisation and scheduling of a definitive procedure. Ideally shunts should therefore be converted to definitive repair at the primary procedure. If this is not possible, they should be removed as soon as patient status allows and within 12 hours of placement, as a logistically practical timeframe.

#### Recommendation 15

Vascular shunts should be considered for conversion to definitive repair as soon as possible, ideally at the primary operation.

Class	Level	References	ToE
Ia	C	Mathew <i>et al.</i> (2017) <sup>123</sup>	

#### 2.13. Which technique should be used for vascular graft reconstruction?

When direct primary suture repair is not possible due to the extent of damage to the artery, graft reconstruction is required. Options for reconstruction are placement of an inline interposition graft, or a bypass graft like those employed in elective vascular surgery. There are no prospective comparative studies in the literature, follow up is limited without consistent recording of long term patency, and there is wide heterogeneity in outcome measures.<sup>124–128</sup>

Whilst vascular surgeons may be more familiar with bypass procedures, there are several benefits to interposition approaches. Interposition grafts are substantially shorter and are associated with longer patency.<sup>124,126</sup> This may be especially important for younger trauma patients who are less likely to take long term anticoagulant medication and more likely to be lost to follow up.<sup>128</sup> Interposition approaches also allow for direct inspection of the injury, debridement of devitalised tissue, and the identification and assessment of concomitant vein and nerve injuries. In anatomically challenging areas with difficult exposure, i.e., thoracic outlet, short interposition grafts may not be possible. A bypass reconstruction is then a better option and when extensive soft tissue defect extra-anatomic bypass has been described.<sup>129</sup>

#### Recommendation 16

Short interposition grafts are recommended in patients with vascular trauma requiring reconstruction.

Class	Level	References	ToE
I	C	Ray <i>et al.</i> (2019), <sup>124</sup> Karmy-Jones <i>et al.</i> (2003), <sup>130</sup> Aksoy <i>et al.</i> (2005), <sup>126</sup> Yagubyan <i>et al.</i> (2004), <sup>127</sup> Lyons <i>et al.</i> (2024) <sup>131</sup>	

#### 2.14. Which graft materials should be used for arterial reconstruction?

Classically, reversed vein grafts have been recommended for vascular reconstruction, although the evidence base for this is historic and based on elective practice in patients with chronic arterial disease requiring long bypasses.<sup>11,132–138</sup> There are no RCTs comparing synthetic and autologous grafts in trauma, with retrospective series subject to substantial biases from patient selection, as use of synthetic grafts may be more common in more severely injured patients.<sup>11,132,136</sup> In complex military vascular trauma with limited non-injured autogenous venous conduits, emergency use of synthetic

grafts may provide an effective limb salvage strategy.<sup>139</sup> After stabilisation and transportation to a higher level of care, elective revascularisation with remaining limited autologous vein can be performed. Therefore, for patients with vascular injury, substantial tissue loss or contamination, and limited non-injured autogenous venous conduits, synthetic grafts have been suggested as a temporary reconstruction, until the wound is clean, fully debrided, and soft tissue coverage can be achieved.<sup>136,138</sup>

Cohort series report similar early patency rates for repair of arterial and venous injuries; long term patency rates are poorly reported.<sup>11,132–138,140</sup> A recent large retrospective databank analysis ( $n = 8\,780$ ) showed that vein conduit was associated with less risk of unplanned return to the operating room and limb loss compared with synthetic grafts.<sup>141</sup> However, synthetic bypass use comprised only 1% of upper extremity injuries and 8% of lower extremity injuries, probably skewing the outcomes and may reflect a selection bias. No study has identified differences in infection rates between synthetic and autologous grafts. Other quoted reasons for using a synthetic graft include long term morbidity from the vein harvest site and the pattern of graft failure in the presence of infection.<sup>136</sup> In the setting of infection, veins tend to disintegrate leading to haemorrhage, whereas synthetic grafts fail at anastomotic lines leading to pseudoaneurysm formation.<sup>136</sup>

Overall, there is no high quality evidence to recommend autologous or synthetic graft material for repair of traumatic vessel injury. This also applies for conduits when venous reconstruction is indicated.<sup>134,142</sup> Synthetic material appears to be a better conduit for the definitive rapid restoration of flow for interposition grafts, while veins may be more suitable for long bypass conduits or for small calibre vessels (such as in paediatric injuries or below the knee or elbow). There is insufficient evidence to assess the role of other graft materials such as bovine patches or human acellular matrix grafts.<sup>137,143</sup>

When a vein is used, standard teaching is to preferentially harvest the vein conduit from the uninjured extremity. However, this practice is not supported by high quality data and can induce long term morbidity in the uninjured limb.<sup>144</sup> In the absence of evidence to the contrary, it is reasonable to harvest the vein from the ipsilateral leg.<sup>145,146</sup>

Recommendation 17			
Synthetic interposition grafts may be considered for emergency definitive vascular repair.			
Class	Level	References	ToE
I <b>ib</b>	C	Hafez <i>et al.</i> (2001), <sup>132</sup> Fox <i>et al.</i> (2005), <sup>11</sup> Lakhwani <i>et al.</i> (2002), <sup>133</sup> Parry <i>et al.</i> (2003), <sup>134</sup> Stonko <i>et al.</i> (2022), <sup>135</sup> Watson <i>et al.</i> (2015), <sup>136</sup> Reilly <i>et al.</i> (2019), <sup>137</sup> Ur Rehman (2020) <sup>138</sup>	

Recommendation 18			
Vein grafts should be considered for vascular reconstruction of arterial injury requiring longer bypass conduits or for small calibre distal vessels.			
Class	Level	References	ToE
I <b>ia</b>	C	Watson <i>et al.</i> (2015), <sup>136</sup> Forsyth <i>et al.</i> (2024) <sup>140</sup>	

### 3. NECK VASCULAR TRAUMA

#### 3.1. Penetrating cervical vascular injury

In penetrating neck trauma, vascular injury occurs in up to 20% of cases, depending on mechanism, with the carotid artery being the most injured.<sup>147–149</sup> The incidence of penetrating vertebral artery injury in civilian and military populations has been reported at 3.1% and 0.3%, respectively.<sup>150</sup>

**3.1.1. Clinical presentation.** Clinical features of penetrating cervical vascular injuries are described as hard signs (rapidly expanding or pulsatile haematoma, severe haemorrhage or difficult to control bleeding, shock refractory to resuscitation, decreased or absent pulse, vascular bruit or thrill, and neurological deficit) and soft signs (haematemesis, minor haemoptysis, dysphonia, dysphagia, and non-expanding haematoma).<sup>151</sup> Stroke is a feared outcome of cervical vascular injuries and may be present initially or emerge during observation or operative treatment.

These ESVS guidelines propose a whole neck approach for the assessment of penetrating neck injuries, rather than the classical three zone description. Wound tracks often cross zone boundaries injuring vascular or aerodigestive structures in other zones.<sup>152–154</sup> This neck zone classification was developed prior to widespread CTA availability. Systematic reviews comparing management strategies provide evidence to support a more comprehensive assessment of the entire neck, complemented by CTA, improving diagnostic accuracy and reducing negative surgical exploration rates.<sup>149,153,155,156</sup>

**3.1.2. Diagnostic imaging.** A patient with neck trauma who is actively bleeding and/or haemodynamically unstable should undergo immediate surgical exploration.<sup>157–159</sup> Literature supports that all other patients should have rapid CTA to define the injuries and guide management.<sup>157,160</sup> Also, for patients with stroke after neck trauma and haemodynamic stability, immediate CTA is appropriate.<sup>158,159,161</sup> Specificity and negative predictive values of CTA in penetrating cervical vascular injury are 97–100%.<sup>95</sup> Large vein injury can be missed on CTA if not bleeding actively at the time of imaging.<sup>95,157</sup>

Recommendation 19			
Immediate open surgical exploration is recommended for patients with penetrating neck injury and active haemorrhage from the wound or expanding haematoma.			
Class	Level	References	ToE
I	C	Bell <i>et al.</i> (2007), <sup>157</sup> Tisherman <i>et al.</i> (2008), <sup>158</sup> Sperry <i>et al.</i> (2013) <sup>159</sup>	



Recommendation 20			
Computed tomography angiography is recommended for all patients with penetrating neck trauma without an indication for immediate operative intervention.			
Class	Level	References	ToE
I	B	Patterson <i>et al.</i> (2012), <sup>95</sup> Karagiorgas <i>et al.</i> (2017) <sup>162</sup>	

**3.1.3. Management.** A summary of the general approach to the management of penetrating cervical carotid or vertebral artery injuries is provided in Table 6.

**3.1.3.1. Penetrating carotid artery injury. ESVS Grade 1 (intimal tear with preserved external arterial contour).**

Injuries to the carotid intima alone, discovered on CTA, are sometimes seen in penetrating neck trauma, more commonly as proximity injuries from gunshot wounds. For injuries with normal external wall contour on CTA, a non-operative management strategy with antithrombotic therapy alone has been reported.<sup>163,164</sup> There are no data on specific antithrombotic agents, but the evidence in general tends to favour the use of a single antiplatelet agent.

Recommendation 21			
Non-operative management with single antiplatelet therapy may be considered for patients with minor (ESVS Grade 1) carotid artery injury due to penetrating trauma.			
Class	Level	References	ToE
Iib	C	Weinberg <i>et al.</i> (2016), <sup>164</sup> Ronaldi <i>et al.</i> (2021) <sup>163</sup>	

**ESVS Grades 2 – 3 (complete wall injury with contained or uncontrolled haemorrhage).**

In patients bleeding from carotid injuries, ligation of the common carotid artery (CCA) or internal carotid artery (ICA) carries a high probability of stroke and death. Repair should therefore be performed whenever possible in patients with surgically accessible carotid injuries.<sup>161,165–168</sup> From North American trauma registry based data, there was a significantly lower in hospital mortality rate when reconstruction was performed for carotid artery injury (ligation vs. reconstruction: 21% vs. 12% for the CCA and 25% vs. 7% for the ICA, respectively).<sup>169</sup> In a South African study, the procedural mortality rate associated with arterial ligation was 45% (9 of 20 patients) and the mortality rate after arterial repair was 17.6% (23/131).<sup>167</sup> Twelve (80%) of 15 surviving patients with a pre-operative neurological deficit who underwent arterial repair had improved neurological status. In another retrospective analysis, of the nine patients with carotid artery ligation, five developed a neurological deficit; the remaining four patients died (100% poor outcomes).<sup>168</sup> Of the 37 patients with blood flow restoration, nine patients died and the neurological deficit persisted in two patients (30% poor outcomes).

**Table 6. Summary of the general approach to the management of penetrating cervical carotid or vertebral artery injuries. Specific management should follow the recommendations above, individualised to the patient, clinical environment, and available resources.**

ESVS Grade	Description	Carotid artery injury	Vertebral artery injury
1	Partial wall injury Normal external wall contour	Single antiplatelet therapy + surveillance	Single antiplatelet therapy + surveillance
2	Complete wall injury Abnormal external wall contour Contained bleeding	Urgent open surgical repair or stent graft treatment	Urgent endovascular therapy
3	Complete wall injury Uncontained haemorrhage	Emergency open surgical repair	Emergency endovascular embolisation or open surgical approach
X	Occlusion	Individualised treatment with common and or internal carotid artery reconstruction, ligation, or antithrombotic or single antiplatelet therapy	Single antiplatelet therapy

Recommendation 22			
Reconstruction rather than ligation of the common or internal carotid artery, when patient physiology allows and technically feasible, is recommended in patients with penetrating ESVS Grade 2 or 3 carotid artery injury.			
Class	Level	References	ToE
I	C	Plotkin <i>et al.</i> (2023), <sup>169</sup> du Toit <i>et al.</i> (2009), <sup>167</sup> Reva <i>et al.</i> (2011), <sup>168</sup> Madsen <i>et al.</i> (2024) <sup>147</sup>	

**ESVS Grade X (occlusion).** The evidence is lacking, with only small case series describing complete occlusion after penetrating carotid injury. The treatment approaches with reconstruction, ligation, or antithrombotic therapy need to be individualised considering the timing of injury presentation, presence and duration of neurological symptoms, injury location (CCA or ICA), extent of occlusion, risk of reperfusion injury, and computed tomography (CT) signs of brain infarction.<sup>147</sup>

**3.1.3.2. Penetrating vertebral artery injury.** Clinical presentation varies from completely asymptomatic to stroke or exsanguinating haemorrhage. In two recent systematic literature reviews ( $n = 462$  and  $n = 169$ , respectively), injury to the proximal vertebral artery carried the highest mortality rate because of associated damage to surrounding vital structures.<sup>150,170</sup>

**ESVS Grade 1 (intimal injury).** Non-operative management with addition of antiplatelet therapy is appropriate for

minimal (ESVS Grade 1) injuries with no neurological symptoms or active haemorrhage.

Recommendation 23			
Non-operative management with single antiplatelet therapy may be considered for patients with an ESVS Grade 1 vertebral artery injury due to penetrating trauma.			
Class	Level	References	ToE
I <b>b</b>	C	Piper et al. (2021), <sup>170</sup> Asensio et al. (2020) <sup>150</sup>	

**ESVS Grade 2 (wall disruption and contained haemorrhage).** Selective operative management has proved safe. Surgical repair of vertebral arteries is challenging due to difficult access. Therefore, endovascular techniques (coiling, covered stenting) have become the first line approach for most cases in the last decades.<sup>150,170</sup> Case reports usually describe technical success with minimal complications, but limited short or long term outcomes have been reported.<sup>171–180</sup> The first choice procedure for vertebral extracranial haemorrhage, pseudoaneurysm, or arteriovenous fistula (AVF) is endovascular embolisation.<sup>181–183</sup> Vertebral artery sacrifice is often harmless, with few post-operative strokes reported (approximately 4%), provided contralateral or posterior circulation collateral flow is intact.<sup>170</sup> The risk of stroke is higher if embolisation is attempted in the distal vertebral artery segment near the posterior inferior cerebellar artery. Asymptomatic AVF can also be managed non-operatively but should be followed up to ensure lack of clinical progression.

Recommendation 24			
Endovascular therapy should be considered as first line treatment for symptomatic or progressing pseudoaneurysm or arteriovenous fistula (ESVS Grade 2) in patients with penetrating vertebral artery injury.			
Class	Level	References	ToE
I <b>a</b>	C	Piper et al. (2021) <sup>170</sup> Asensio et al. (2020) <sup>150</sup>	

**ESVS Grade 3 (uncontrolled haemorrhage).** Immediate endovascular therapy is preferred for severe haemorrhage (active haemorrhage, hypovolaemic shock, expanding haematoma) due to vertebral artery injury if possible. If not possible, a surgical approach with vertebral artery ligation is suggested.<sup>170,181</sup> Surgical techniques may include arterial ligation, primary repair, transposition of the vertebral artery to the carotid artery (for proximal injuries), and packing.<sup>170</sup>

Recommendation 25			
Emergency endovascular management with embolisation if feasible is recommended for patients with penetrating extracranial vertebral artery injury and uncontrolled haemorrhage (ESVS Grade 3).			
Class	Level	References	ToE
I	C	Piper et al. (2021), <sup>170</sup> Asensio et al. (2020) <sup>150</sup>	

**ESVS Grade X (occlusion).** Non-operative management has been suggested for asymptomatic vertebral artery occlusions.<sup>184</sup> From registry data from the National Trauma Data Bank, in hospital stroke after penetrating vertebral artery injuries in general is relatively uncommon and principally related to patient factors and associated injuries.<sup>171</sup> Specific data are lacking on the use of antithrombotic or antiplatelet therapy.<sup>171</sup>

Recommendation 26		
Non-operative management with single antiplatelet therapy should be considered for patients with penetrating extracranial vertebral artery injury and occlusion (ESVS Grade X) without neurological symptoms.		
Class	Level	References
I <b>a</b>	C	Consensus

**3.1.3.3. Penetrating cervical venous injury.** An injury to the internal jugular vein should be repaired if possible but may be ligated in a haemodynamically unstable situation.<sup>185</sup> If there are bilateral internal jugular vein injuries, repair of at least one vein should be attempted.<sup>148</sup> The external jugular vein can be ligated without consequence.

Recommendation 27		
Ligation is recommended if repair of internal jugular vein injury is not easily achievable, provided one internal jugular vein remains patent.		
Class	Level	References
I	C	Consensus

### 3.2. Blunt cervical vascular injury

Blunt cervical vascular injury (BCVI) has an incidence of 1 – 5% in severely injured patients, with an up to four times higher incidence for patients with high impact trauma and associated craniomaxillofacial fractures.<sup>16,95,186–188</sup>

**3.2.1. Clinical presentation.** Blunt injuries are most commonly asymptomatic on presentation and are detected on CTA. Patients may present with symptoms of stroke due to carotid occlusion or embolism, but an occlusion may also be asymptomatic. A more common clinical presentation is the delayed presentation of stroke due to thromboembolic complications of an intraluminal injury (ESVS Grade 1 or 2). BCVI very rarely presents with the clinical signs associated with penetrating neck injury and almost never causes active free bleeding and haemorrhagic shock.

Recommendation 28		
Clinical examination alone is not recommended to rule out cervical vascular injury in patients with blunt neck trauma.		
Class	Level	References
I <b>IIb</b>	C	Consensus

**3.2.2. Diagnostic imaging.** For blunt cerebrovascular injury, the diagnostic modality of choice is CTA from the aortic arch and including the extra- and intracranial vessels. Specificity and negative predictive values of CTA for BCVI have been reported as high as 82 – 100% and 90 – 99%, respectively.<sup>95,189–191</sup>

Recommendation 29			
Computed tomography angiography including intracerebral vessels is recommended for all patients at risk of blunt cerebrovascular injury.			
Class	Level	References	ToE
I	B	Patterson <i>et al.</i> (2012), <sup>95</sup> Karagiorgas <i>et al.</i> (2017) <sup>162</sup>	

The rationale behind screening trauma patients with a neck CTA is to identify patients with BCVI at risk of vascular injury causing bleeding, pseudoaneurysm, or thrombosis leading to stroke, and who may need medical or operative treatment. Exactly which patients should be screened remains unclear. Multiple screening protocols have been proposed, all including both signs and symptoms of BCVI and risk factors based on trauma mechanism or associated injuries.<sup>186,192–197</sup> Too liberal screening leads to over triage, potential over treatment, and unnecessary radiation exposure, while too strict protocols lead to missed treatment opportunities.<sup>198</sup> No direct prospective comparative or randomised studies between different screening tools were identified, but the modified Denver criteria (Table 7) are the most extensively studied and widely adopted.<sup>186,192,199</sup> Without clear evidence to support the use of one particular screening tool, institutions should implement one of these screening protocols and adjust if required to local resources and trauma patterns.

Recommendation 30			
The use of screening protocols to identify cervical vascular injury early should be considered for patients with blunt trauma.			
Class	Level	References	ToE
Iia	C	Brommeland <i>et al.</i> (2018), <sup>192</sup> Geddes <i>et al.</i> (2016), <sup>186</sup> Biffi <i>et al.</i> (1999), <sup>193</sup> Biffi <i>et al.</i> (2009), <sup>194</sup> Leichtle <i>et al.</i> (2020), <sup>196</sup> Jacobson <i>et al.</i> (2015), <sup>195</sup> Black <i>et al.</i> (2021) <sup>197</sup>	

**3.2.3. Management**

**3.2.3.1. Blunt carotid artery injury. ESVS Grade 1 (intimal tear, dissection, intramural haematoma).** For patients with low grade, blunt carotid artery injuries, non-operative management with antithrombotic therapy has support in the literature.<sup>192,200</sup>

**Table 7.** Example of screening protocols, the expanded Denver screening criteria for blunt cervical vascular injury (BCVI). Computed tomography angiography (CTA) is indicated if at least one criterion is present.<sup>186</sup>

Signs/symptoms of BCVI
Arterial haemorrhage from neck, nose, or mouth
Cervical bruit in patients aged <50 years
Expanding cervical haematoma
Focal neurological deficit
Neurological examination incongruous with head CT findings
Stroke on secondary CT scan
Risk factors for BCVI (high energy transfer mechanism with):
Le Fort II or III midface fracture
Mandible fracture
Complex skull fracture, basilar skull fracture, or occipital condyle fracture
Severe TBI with GCS score <6
Cervical spine fracture, subluxation, or ligamentous injury at any level
Near hanging with anoxic brain injury
Seat belt abrasion with significant swelling, pain, or altered mental status
TBI with thoracic injury
Scalp degloving
Thoracic vascular injury
Blunt cardiac rupture
Upper rib fracture

BCVI = blunt cervical vascular injury; CT = computed tomography; TBI = traumatic brain injury; GCS = Glasgow Coma Scale.

Recommendation 31			
Non-operative management with single antiplatelet therapy is recommended for patients with blunt, low grade carotid artery injury (ESVS Grade 1).			
Class	Level	References	ToE
I	C	Russo <i>et al.</i> (2021), <sup>201</sup> Brommeland <i>et al.</i> (2018), <sup>192</sup> Murphy <i>et al.</i> (2021), <sup>202</sup> Shahan <i>et al.</i> (2016), <sup>203</sup> Momic <i>et al.</i> (2024) <sup>204</sup>	

**ESVS Grade 2 (external wall disruption, pseudoaneurysm).**

High grade blunt carotid artery injuries (ESVS Grade 2, e.g., pseudoaneurysm) are less likely to heal compared with low grade ones (ESVS Grade 1).<sup>205,206</sup> However, the natural history of carotid pseudoaneurysms is that the overwhelming majority will heal over time, but the incidence of stroke quadrupled (20% vs. 4.8%) and mortality increased nearly ten fold (36.7% vs. 3.8%) when antithrombotic therapy was withheld.<sup>201</sup> Therefore, antithrombotic treatment has dominated, with endovascular repair reserved for a select few.<sup>201</sup>

The benefit of stenting for more severe blunt carotid artery injuries is controversial and limited by stroke as a result of in stent thrombosis.<sup>201,207</sup> Endovascular treatment (stent graft or stent) has been reserved for pseudoaneurysms progressing in size (size threshold of >10mm has been suggested) or severe stenosis with thrombotic and or

ischaemic symptoms.<sup>192,208-210</sup> The selection of patients who will benefit the most from endovascular therapy needs further evaluation.<sup>192,201</sup>

Recommendation 32			
The use of routine endovascular stenting as an adjunct to antithrombotic therapy is not recommended for patients with blunt carotid artery injury without active bleeding (ESVS Grade 1 or 2).			
Class	Level	References	ToE
IIIb	C	Russo <i>et al.</i> (2021), <sup>201</sup> Weber <i>et al.</i> (2018), <sup>16</sup> Brommeland <i>et al.</i> (2018), <sup>192</sup> Kim <i>et al.</i> (2020) <sup>210</sup>	

Recommendation 33			
Delayed endovascular treatment may be considered for patients with blunt carotid or vertebral artery injury and enlarging pseudoaneurysm (ESVS Grade 2) or neurological symptoms.			
Class	Level	References	ToE
IIb	C	Lauerman <i>et al.</i> (2015), <sup>209</sup> Shahan <i>et al.</i> (2018), <sup>208</sup> Mei <i>et al.</i> (2014), <sup>211</sup> Burlew <i>et al.</i> (2014), <sup>212</sup> DiCocco <i>et al.</i> (2011) <sup>213</sup>	

**ESVS Grade 3 (uncontained bleeding).** ESVS Grade 3 injuries are rare after BCVI, but continuous bleeding and or expanding cervical haematomas should be treated by stent graft or surgical exploration.

Recommendation 34			
Operative treatment with open repair or endovascular stent graft is recommended for patients with blunt carotid artery injury and active haemorrhage (ESVS Grade 3).			
Class	Level	References	ToE
I	C	Consensus	

**ESVS Grade X (occlusion).** Occlusive carotid injuries carry a risk of stroke and can be challenging to manage. For patients with a complete carotid artery occlusion after blunt injury and normal neurological examination, observation and anticoagulation seem an acceptable approach, but the evidence is lacking with only small case series described. Antithrombotic treatment alone has been suggested for occlusions of the ICA especially if complete and extending to the skull base.<sup>201</sup> If neurological symptoms are present in the context of carotid artery occlusion, an individualised approach seems reasonable, taking into account prognostic factors for decision making such as haemodynamics, duration of neurological deficit, and risk of reperfusion injury, coma, and CT verified brain infarction. The available evidence here is very limited to direct management.

Recommendation 35		
Non-operative management with single antiplatelet therapy should be considered for patients with blunt carotid injury and complete occlusion (ESVS Grade X) without neurological symptoms.		
Class	Level	References
IIa	C	Consensus

Recommendation 36		
Management of blunt carotid injury and complete occlusion (ESVS Grade X) with neurological symptoms should be considered on an individual basis, including the duration of neurological symptoms, risk of reperfusion injury, and signs of brain infarction on computed tomography.		
Class	Level	References
IIa	C	Consensus

**3.2.3.2. Blunt vertebral artery injury.** The most common anatomic location of blunt vertebral artery injury is the mid or distal section of the vessel.<sup>214,215</sup> The risk of stroke is lower in vertebral than in carotid artery injuries.<sup>216</sup>

Treatment modalities for low grade injuries (ESVS Grade 1) have been studied in case series including traumatic, spontaneous, and iatrogenic causes, and available evidence is not focused specifically on trauma patients. Non-operative treatment with antithrombotics has been the first choice. Spontaneous arterial healing during the initial six months post injury is likely.<sup>214,217</sup>

For higher grade injuries (ESVS Grade 2), pseudoaneurysms in general have a benign course, most will not cause symptoms (< 5% transient ischaemic attack or stroke rate, < 15% recurrence of non-ischaemic symptoms) or enlarge on follow up (< 15%), and can be managed by antithrombotic therapy.<sup>215</sup> Endovascular techniques with embolisation or stenting are used for patients with vertebral haemorrhage, recurrent cerebral ischaemic events despite antithrombotic therapy, or enlarging pseudoaneurysms.<sup>211,215,218,219</sup> If endovascular therapy is not possible, a surgical approach with vertebral artery ligation is suggested in patients with uncontrolled haemorrhage. Non-operative management with antiplatelet therapy seems reasonable for asymptomatic blunt vertebral artery occlusions (ESVS Grade X).<sup>184</sup>

Recommendation 37			
Management with antiplatelet therapy as first line treatment is recommended for patients with blunt vertebral artery injury without active haemorrhage (ESVS Grades 1, 2, or X).			
Class	Level	References	ToE
I	B	Markus <i>et al.</i> (2019), <sup>220</sup> Rosati <i>et al.</i> (2020), <sup>221</sup> Patel <i>et al.</i> (2020), <sup>214</sup> Daou <i>et al.</i> (2017) <sup>222</sup>	

Recommendation 38		
Emergency endovascular management with embolisation, if feasible, is recommended for patients with blunt extracranial vertebral artery injury and uncontrolled haemorrhage (ESVS Grade 3).		
Class	Level	References
I	C	Consensus

**3.2.3.3. Antithrombotic therapy.** Antithrombotic treatment for stroke prevention is the mainstay of BCVI treatment and should be started as soon as the diagnosis is made.<sup>222–224</sup> Initiating systemic antithrombotic treatment to the multiple injured trauma patient needs to be weighed against any potential bleeding risks such as worsening of intracranial haemorrhage or haematomas in solid organs, but there should be a high threshold for withholding antithrombotic treatment for BCVI.<sup>188,199,201,203,204,225</sup>

A systematic review of asymptomatic BCVI showed that any choice of antithrombotic therapy was better than no treatment, but no specific differences between type of antithrombotic therapy and stroke outcomes were found.<sup>202</sup> Other studies have also reported similar benefits and risks with antiplatelets or anticoagulants.<sup>201,220,222</sup> However, a recent meta-analysis showed that the stroke rate after BCVI was lower for patients treated with antiplatelets than with anticoagulants (OR 0.57, 95% CI 0.33 – 0.96). For the studies specifically comparing aspirin with heparin, the stroke rate was similar between groups (OR 0.43, 95% CI 0.15 – 1.20).<sup>204</sup> There was a lower bleeding risk with antiplatelets than with anticoagulants (OR 0.29, 95% CI 0.13 – 0.63;  $p = .002$ ). When specifically evaluating the risk of bleeding complications with aspirin vs. heparin, aspirin showed lower rates of bleeding complications (OR 0.16, 95% CI 0.04 – 0.58). There is no evidence of additional benefit of dual compared with single antiplatelet treatment.<sup>201,222</sup> Some centres initiate treatment with low molecular weight heparin (LMWH) or systemic heparinisation and change early (after 24 – 48 hours) to antiplatelet treatment.<sup>192</sup> There is insufficient evidence to make recommendations for this treatment option.<sup>204</sup> Treatment should be continued for at least three months or discontinued earlier if the BCVI has resolved after imaging.<sup>192,203–205,220</sup> There are no data to assess the role of direct oral anticoagulants (DOACs) as alternatives.

For cervical vascular dissections, the CADISS (Cervical Artery Dissection in Stroke Study) trial with the inclusion criteria of extracranial carotid ( $n = 118$ ) or vertebral ( $n = 132$ ) artery dissections, not entirely traumatic, with neurological symptom onset within the last seven days, in combination with imaging evidence of definite or probable dissection, found no significant difference in outcomes between antiplatelet or anticoagulation regimens for three to six months, with annual recurrent stroke rates of 0.3 – 3.4% and transient ischaemic attack rates of 0.6 – 1.7%.<sup>220</sup> The COMPASS (Cardiovascular Outcomes for People Using Anticoagulation Strategies) registry reported similar outcomes but again not in a specific trauma population.<sup>221</sup> These two pragmatic studies included

**Table 8.** Summary of the general approach to the management of blunt carotid or vertebral artery injuries. Specific management should follow the recommendations above, individualised to the patient, clinical environment and available resources.

ESVS Grade	Description	Carotid artery injury	Vertebral artery injury
1	Partial wall injury Normal external wall contour	Single antiplatelet therapy + surveillance	Single antiplatelet therapy + surveillance
2	Complete wall injury Abnormal external wall contour Contained bleeding	Single antiplatelet therapy + surveillance Selective endovascular treatment	Single antiplatelet therapy + surveillance Selective endovascular treatment
3	Complete wall injury Uncontained haemorrhage	Open surgical or endovascular repair	Endovascular embolisation if possible, otherwise open surgical approach
X	Occlusion	No neurological symptoms: single antiplatelet therapy Neurological symptoms: individualised approach	Single antiplatelet therapy

different pharmacological regimens (aspirin; clopidogrel; dipyridamole; aspirin and clopidogrel; aspirin and dipyridamole; heparin and warfarin; warfarin alone).<sup>220,221</sup>

In summary, there is no higher level of evidence to recommend a specific antithrombotic agent for BCVI treatment, although the evidence tends to favour the use of a single antiplatelet agent. Antiplatelet therapy seems to have lower rates of bleeding complications in the trauma setting. Given the evidence on the efficacy and safety of low dose aspirin, these guidelines recommend single antiplatelet therapy as the first line antithrombotic regimen for BCVI (Table 8).

**3.2.3.4. Surveillance of blunt cervical vascular injury.** A follow up CTA after approximately seven to ten days of BCVI has been suggested in order to confirm the diagnosis or rule out false positive findings (e.g., vessel spasm, low flow, and contrast that mimics occlusion).<sup>192,200</sup> At this time, around 50% of low grade injuries (ESVS Grade 1) have resolved while 10% have progressed, leading to changes in management. Long term, most low grade carotid injuries will heal.<sup>202</sup>

Early surveillance imaging has been questioned for higher grade injuries (ESVS Grade 2) as it rarely leads to management changes, and a three month surveillance image may be sufficient. It has been suggested that blunt carotid arterial injuries that resolve spontaneously do so within three to twelve months.<sup>226</sup> A three month repeat CTA could guide the continuation or discontinuation of antiplatelet

medication.<sup>192</sup> It is unclear whether long term follow up is beneficial. In a systematic review, more than 95% of post-dissection internal carotid pseudoaneurysms remained unchanged and asymptomatic, but only a few of the included cases were considered post-traumatic.<sup>227</sup>

Recommendation 39		
Surveillance with computed tomography angiography at one week and three months should be considered for patients with blunt carotid artery injury (ESVS Grade 1 or 2) undergoing non-operative management with antiplatelet treatment.		
Class	Level	References
Ila	C	Consensus

**3.2.4. Post-operative antithrombotic therapy.** The choice and duration of post-operative antithrombotic therapy after carotid repair varies in the literature and no consensus agreement yet exists to provide guidance for the need for anticoagulation and, if so, the type that should be used. For antithrombotic therapy after stent placement, in an older review antiplatelet agents were used (55.8%) most often compared with warfarin (17.7%), LMWH (15.9%), and a combination of agents (1.8%).<sup>207</sup> In trauma patients, post-procedural dual antiplatelet treatment may be associated with an increased risk of bleeding, and each case needs to be considered individually.<sup>192,194,219,228</sup> Post-operative antithrombotic combinations have been described for durations ranging from three months to lifelong therapy.<sup>213,228,229</sup>

## 4. THORACIC AORTA AND THORACIC OUTLET VASCULAR TRAUMA

### 4.1. Blunt thoracic aortic injury

Traumatic blunt thoracic aortic injury (BTAI) is associated with a high mortality rate with up to 80% of patients dying before their arrival at hospital.<sup>230–232</sup> The pathophysiology of BTAI relates to the transition from the mobile aortic arch to fixed thoracic aorta. The most common location is the aortic isthmus in 80 – 90% of patients admitted.<sup>49</sup>

**4.1.1. Clinical presentation.** The vast majority of BTAs are asymptomatic and are diagnosed on imaging only. For those that do rupture, the risk is highest in the first few hours after the injury. In an American Association for the Surgery of Trauma (AAST) multicentre study from the 1990s, 24 (8.8%) of the 274 patients in the study population were admitted to hospital in a stable condition and progressed to free rupture in the following 30 hours.<sup>231</sup> However, rigorous blood pressure control reduces the risk of rupture to about 1.5%.<sup>233</sup> The systolic blood pressure should be controlled usually in the range of 90 – 110 mmHg, depending on the presence of hypovolaemic shock or traumatic brain injury (TBI), and the heart rate < 100 beats per minute to

minimise wall shear stress and decrease the potential for expansion or rupture.<sup>232,234–239</sup> Administration of intravenous beta blockers with close cardiovascular monitoring is the most used modality for acute blood pressure and heart rate control.<sup>240</sup>

Outcomes for patients with aortic diseases have been improved with the centralisation of care in high volume trauma centres. Treatment of BTAI requires similar expertise as for other aortic pathologies and should be managed in trauma centres with aortic surgeons offering open and endovascular aortic treatment modalities.<sup>232,234,235,237,241–243</sup>

Recommendation 40			
Systolic blood pressure (90 – 110 mmHg) and heart rate (<100/minute) control are recommended for patients with untreated blunt thoracic aortic injury except in the presence of hypovolaemic shock or traumatic brain injury.			
Class	Level	References	ToE
I	C	Fabian <i>et al.</i> (1998), <sup>234</sup> Neschis <i>et al.</i> (2008), <sup>232</sup> Bossone <i>et al.</i> (2021), <sup>235</sup> Gaffey <i>et al.</i> (2020), <sup>236</sup> Osgood <i>et al.</i> (2014), <sup>237</sup> Jacob-Brassard <i>et al.</i> (2019) <sup>238</sup>	

Recommendation 41			
Referral to a trauma centre with 24/7 multispecialty expertise to treat aortic pathology is recommended for all patients with blunt thoracic aortic injury.			
Class	Level	References	ToE
I	C	Ultee <i>et al.</i> (2016), <sup>241</sup> Mohapatra <i>et al.</i> (2021), <sup>243</sup> MacKenzie <i>et al.</i> (2006) <sup>242</sup>	

**4.1.2. Diagnostic imaging.** Chest radiography is a poor screening test and a significant number of aortic injuries will not show any mediastinal abnormalities on plain Xray.<sup>244–246</sup> CTA of the thorax is now the primary diagnostic tool for BTAI in all trauma centres. Multislice CTA with 3D reconstruction has been shown to have almost 100% sensitivity and specificity, a 90% positive predictive value, and a 100% negative predictive value with an overall diagnostic accuracy of 99.7%.<sup>247,248</sup> Furthermore, CTA of the aorta with 3D reconstruction allows both delineation of the injury severity and planning and access for endovascular repair.

Recommendation 42			
Chest Xray is not recommended as an imaging technique to exclude blunt thoracic aortic injury.			
Class	Level	References	ToE
IIIb	C	Bruckner <i>et al.</i> (2006), <sup>249</sup> Gutierrez <i>et al.</i> (2016), <sup>250</sup> Downing <i>et al.</i> (2001), <sup>251</sup> Ho <i>et al.</i> (2002) <sup>246</sup>	

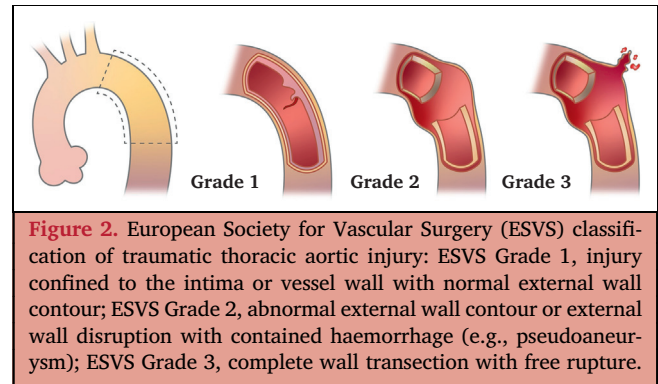
Recommendation 43			
Computed tomography angiography of the aorta is recommended for the diagnosis and characterisation of blunt thoracic aortic injury.			
Class	Level	References	ToE
I	B	Bruckner <i>et al.</i> (2006), <sup>249</sup> Katayama <i>et al.</i> (2018), <sup>252</sup> Gutierrez <i>et al.</i> (2016), <sup>250</sup> Fabian <i>et al.</i> (1998), <sup>234</sup> Patterson <i>et al.</i> (2012), <sup>95</sup> Ho <i>et al.</i> (2002), <sup>246</sup> Fox <i>et al.</i> (2015), <sup>253</sup> Evangelista <i>et al.</i> (2023) <sup>254</sup>	

**4.1.3. Grading of thoracic aortic lesions.** The morphology of the thoracic aortic lesion on CTA reflects the severity of the injury and has been integrated into several grading systems, the most used of which was adopted by the SVS BTAI guidelines in 2011 and which is consistent with the ESVS grading system (Fig. 2; Table 9) (ESVS Grade 1 = SVS Grade I + II; ESVS Grade 2 = SVS Grade III; ESVS Grade 3 = SVS Grade IV).<sup>239,255–258</sup> Among patients with BTAI who present to the hospital, approximately 40% are ESVS Grade 1, 50% ESVS Grade 2, and 10% ESVS Grade 3.<sup>240</sup>

**4.1.4. Management of thoracic aortic injury.** The optimal time from injury or admission to thoracic aortic repair should be individualised according to other severe injuries, the physiological status of the patient, and the grade of aortic injury.

**4.1.4.1. Minor aortic injuries (ESVS Grade 1).** Minor aortic injuries (ESVS Grade 1) are defined as an intimal tear and or intramural haematoma without external contour abnormality. These injuries are supported in the literature to be managed with blood pressure control and observation with regular CTA follow up until resolution of the aortic lesion. A repeat CTA within 48 – 72 hours of admission to assess aortic lesion stability is appropriate. In a small prospective series of 58 patients, Fabian *et al.* reported that blood pressure control with beta blockade and sodium nitroprusside prevented in hospital ruptures, and this is now a standard component of BTAI management.<sup>234,259,260</sup> The SVS guidelines suggests that the heart rate should be <100/minute and the systolic blood pressure around 100 mmHg.<sup>239</sup> Hypotension should be avoided in patients with concomitant major head trauma who require pharmacological blood pressure support to maintain cerebral perfusion.<sup>240,261</sup> In patients with concomitant major head trauma, thoracic endovascular aortic repair (TEVAR) may be indicated to maintain cerebral perfusion with higher blood pressures. There is a lack of treatment evidence for the combination of BTAI and TBI, and decisions on blood pressure control or stent graft need to be individualised.

For ESVS Grade 1 aortic injuries with intramural haematoma, older guidance recommended endovascular repair.<sup>239</sup> However, recent studies have shown that these injuries can



also be safely managed non-operatively with very low rates of disease progression and aortic related death.<sup>237</sup> The largest study to date regarding the natural history of non-operatively managed BTAI with aortic wall haematoma demonstrated no evidence of disease progression up to a five year follow up.<sup>236</sup> Recent data from the Aortic Trauma Foundation international registry also demonstrated no failures of medical therapy in SVS Grade II patients and no aortic related deaths.<sup>240</sup> In a patient cohort with minimal aortic injuries managed medically, the median injury resolution time was 39 days for intimal tears and 62 days for aortic wall haematoma injuries.<sup>262</sup> While the existing data suggest that non-operative management of all ESVS Grade 1 injuries is safe, further studies with long term CTA follow up are required, ideally in the context of a prospective multi-centre study.<sup>263</sup>

Recommendation 44			
Non-operative management with blood pressure control and follow up imaging is recommended in patients with ESVS Grade 1 blunt thoracic aortic injury without concomitant severe traumatic brain injury.			
Class	Level	References	ToE
I	C	Yadavalli <i>et al.</i> (2023), <sup>264</sup> Jacob-Brassard <i>et al.</i> (2019), <sup>238</sup> Soong <i>et al.</i> (2019), <sup>265</sup> Fox <i>et al.</i> (2015), <sup>253</sup> Demetriades <i>et al.</i> (2009), <sup>266</sup> Alarhayem <i>et al.</i> (2021), <sup>267</sup> Harris <i>et al.</i> (2016), <sup>258</sup> DuBose <i>et al.</i> (2015), <sup>260</sup> Starnes <i>et al.</i> (2012) <sup>257</sup>	

Recommendation 45			
Endovascular stent graft repair may be considered in patients with ESVS Grade 1 blunt thoracic aortic injury and concomitant severe traumatic brain injury when blood pressure control is not feasible.			
Class	Level	References	ToE
Iib	C	Rabin <i>et al.</i> (2014), <sup>261</sup> Arbabi <i>et al.</i> (2022) <sup>268</sup>	

**Table 9. Suggested management approach for blunt thoracic aortic injury (BTAI) based on grade of aortic injury.**

ESVS Grade	SVS Grade	Description	Management
1	I and II	Injury confined to the intima or vessel wall with normal external wall contour	Non-operative: repeat CTA within 48 – 72 hours to assess aortic lesion stability Major traumatic brain injury: delayed TEVAR
2	III	Abnormal external wall contour or external wall disruption with contained haemorrhage (e.g., pseudoaneurysm)	Low risk BTAI features: delayed (>24 h) TEVAR. Stabilisation of other major traumatic injuries first High risk BTAI features: urgent (<24 h) TEVAR
3	IV	Complete wall transection with free rupture	Emergency TEVAR

ESVS = European Society for Vascular Surgery; SVS = Society for Vascular Surgery; CTA = computed tomography angiography; TEVAR = thoracic endovascular aortic repair; BTAI = blunt thoracic aortic injury.

**4.1.4.2. Pseudoaneurysms (ESVS Grade 2).** Thoracic aortic injury (ESVS Grade 2), defined as having any external wall contour abnormality, such as a pseudoaneurysm, should undergo TEVAR. There is controversy in clinical practice around the optimal timing of repair. High risk features for urgent repair have been suggested to include signs of hypotension (systolic blood pressure < 90 mmHg), left haemothorax, very large mediastinal haematoma, and mass effect causing aortic coarctation (Table 10).<sup>257,259,269</sup> These radiological findings may be indicative of more severe aortic trauma.<sup>256,269</sup>

For these ESVS Grade 2 injuries, many studies suggest that repair after 24 hours is safe and may benefit patients with other injuries. The status of associated organ injuries is crucial when planning operative management of BTAI.<sup>234</sup> Unstable pelvic, liver, spleen, other vascular, and abdominal injuries, or long bone fractures that might need immediate surgical repair, could be performed before TEVAR.

Rabin *et al.* found that early aortic intervention (< 24 hours) was independently associated with an increased aortic morbidity and mortality rate, regardless of repair modality or anticoagulation.<sup>261</sup> The results of the AAST Aortic Injury Study Group suggested that patients treated in a delayed fashion (> 24 hours) after a period of optimisation had improved survival compared with patients with BTAI treated within 24 hours.<sup>266</sup> In the AAST multicentre prospective study, the mean time from injury to repair was 10.2 hours in the early group and 126.2 hours in the delayed group.<sup>49</sup> The overall mortality in the delayed repair group was statistically significantly lower than the early repair group (5.8% vs. 16.5%;  $p = .034$ ). Multivariable

**Table 10. High risk features for urgent treatment of blunt thoracic aortic injury.**<sup>257,259,269</sup>

High risk features
Large mediastinal haematoma
Left haemothorax
Aortic coarctation
Large pseudoaneurysm
Systolic blood pressure < 90 mmHg
Traumatic brain injury

analysis showed a statistically significantly increased risk of death in the early repair group (adjusted OR 7.78, 95% CI 1.69 – 35.70;  $p = .008$ ). The survival benefits in the delayed repair group were present even for the subgroup without associated major injuries. Subsequent studies have confirmed that delayed repair is an independent factor protective against death.<sup>270</sup> The current evidence supports delayed aortic repair, and that it is not only safe but may be preferable in selected patients, provided there is good blood pressure control.

An international prospective multicentre registry identifying patients with BTAI (SVS grade I, 3%; grade II, 10%; grade III, 78%; grade IV, 9%) with concomitant TBI showed no difference in delayed cerebral ischaemic events, in hospital death, or aortic related deaths between patients who had undergone TEVAR at emergency (< 6 hours vs. ≥ 6 hours) or urgent (< 24 hours vs. ≥ 24 hours) intervals.<sup>268</sup> It was concluded that the timing of TEVAR did not influence the outcomes, but as a study limitation patient condition and other requirements could possibly have had an important influence on the selection of TEVAR timing. The decision to intervene should therefore be guided by individual patient factors, such as haemodynamic status and the presence of associated injuries rather than the timing of TEVAR.<sup>268</sup>

**Recommendation 46**

**Delayed (> 24 hour) endovascular stent graft repair should be considered for patients with blunt thoracic aortic injury and any external wall contour abnormality (ESVS Grade 2) if there are no high risk injury features.\***

Class	Level	References	ToE
Ia	C	Yadavalli <i>et al.</i> (2024), <sup>271</sup> Jacob-Brassard <i>et al.</i> (2019), <sup>238</sup> Soong <i>et al.</i> (2019), <sup>265</sup> Fox <i>et al.</i> (2015), <sup>253</sup> Marcaccio <i>et al.</i> (2018), <sup>272</sup> McCurdy <i>et al.</i> (2020), <sup>273</sup> Romijn <i>et al.</i> (2023), <sup>274</sup> Zambetti <i>et al.</i> (2022), <sup>275</sup> Alarhayem <i>et al.</i> (2021), <sup>267</sup> Demetriades <i>et al.</i> (2009) <sup>266</sup>	

\* See Table 10.



Recommendation 47			
Urgent (<24 hour) endovascular stent graft repair is recommended for patients with blunt thoracic aortic injury and any external contour abnormality (ESVS Grade 2) with high risk aortic features.*			
Class	Level	References	ToE
I	C	DuBose <i>et al.</i> (2015), <sup>260</sup> Yadavalli <i>et al.</i> (2024), <sup>271</sup> Jacob-Brassard <i>et al.</i> (2019), <sup>238</sup> Soong <i>et al.</i> (2019), <sup>265</sup> Fox <i>et al.</i> (2015), <sup>253</sup> Marcaccio <i>et al.</i> (2018), <sup>272</sup> Romijn <i>et al.</i> (2023), <sup>274</sup> Alarhayem <i>et al.</i> (2021), <sup>267</sup> Harris <i>et al.</i> (2015), <sup>269</sup> Starnes <i>et al.</i> (2012) <sup>257</sup>	

\* See Table 10.

**4.1.4.3. Severe aortic injury (ESVS Grade 3).** Severe aortic injuries (ESVS Grade 3) with active extravasation (complete transection and free rupture) should be taken for immediate repair.<sup>256</sup> Endovascular stent graft repair is the strongly preferred intervention if resources can be mobilised quickly. In settings with limited resources or in young paediatric patients with unsuitable anatomy, open surgical repair (OSR) might be the only operative alternative.

Recommendation 48			
Immediate operative repair is recommended for patients with blunt thoracic aortic injury with active extravasation (ESVS Grade 3).			
Class	Level	References	ToE
I	C	Yadavalli <i>et al.</i> (2024), <sup>271</sup> Jacob-Brassard <i>et al.</i> (2019), <sup>238</sup> Soong <i>et al.</i> (2019), <sup>265</sup> Fox <i>et al.</i> (2015) <sup>253</sup>	

#### 4.1.5. Operative management of blunt thoracic aortic injury

**4.1.5.1. Endovascular repair.** TEVAR for traumatic thoracic aortic injuries was first reported in 1997.<sup>276</sup> The shift towards endovascular treatment is clearly demonstrated by two large prospective studies by the AAST in 1997 (AAST1) and 2007 (AAST2).<sup>40,231</sup> In 1997, all 207 cases with BTAI were managed by OSR, whereas in 2007, 65% of the 193 cases were managed with endovascular stent grafts and only 35% by open repair. In the largest multicentre retrospective BTAI examination to date, conducted by the Aortic Trauma Foundation between 2008 and 2013, TEVAR was the treatment for 76.4% of the 382 patients with BTAI studied.<sup>260</sup> Rates in most established trauma centres now approach 100% for BTAI to the descending aorta.

Endovascular repair is associated with significantly better early outcomes than open repair. In the AAST2 study, multivariable analysis showed a significantly lower adjusted mortality rate and fewer blood transfusions in the endovascular group compared with the open repair group. In the subgroup of patients with critical extra-thoracic injuries, TEVAR was associated with a significant survival benefit compared with OSR.<sup>49</sup> In a meta-analysis of 699 procedures in which 370 patients were treated by endovascular repair and 329 patients were managed by OSR, the observed mortality rates were 7.6% and 15.2% ( $p = .008$ ), respectively. The incidence of procedure related paraplegia was 5.6% in the OSR group and 0% in the endovascular group. The incidence of stroke was likewise statistically significantly lower in the TEVAR group (0.8% vs. 5.3%;  $p = .003$ ).<sup>277</sup>

Despite improved outcomes with TEVAR compared with OSR, there are device related complications including endoleaks, access site vessel complications, occlusion of the left subclavian or left common carotid arteries, and device collapse associated with stent graft placement.<sup>49,253,278</sup> Intra-operative systemic heparinisation needs to be individualised based on the balance between the perceived risks of organ bleeding or severity of TBI and peri-procedural thromboembolic complications.

Recommendation 49		
Intra-operative systemic heparinisation for thoracic aortic stent graft repair should be considered individualised, including the perceived risks of bleeding, thromboembolic complications, and severity of traumatic brain injury.		
Class	Level	References
IIa	C	Consensus

**4.1.5.1.1. Stent graft oversizing.** The presence of an endoleak after TEVAR was observed in around 14% of patients.<sup>279,280</sup> The correct size of stent graft is essential in avoiding complications such as type I endoleak or stent collapse. Routinely, optimal deployment of the stent graft requires oversizing the device by 10 – 20% but increasing the degree of oversizing up to 30% may be considered in hypovolaemic patients.<sup>279–281</sup> Intravascular ultrasound has limited evidence, and repeat CTA for planning is an alternative in patients reaching a normovolaemic state.<sup>282,283</sup> Excessive oversizing of the stent graft may cause collapse of the device with potentially catastrophic consequences. Severe aortic arch angulation can result in poor apposition between the stent graft and the thoracic aortic wall, especially at the inner curve.<sup>284</sup> Many of these problems have been addressed with the improvement of stent grafts, which are now available in curved shapes more suited to the thoracic aorta of younger patients.

Recommendation 50			
<b>Stent graft oversizing between 20% and 30%, depending on the hypovolaemic status during index computed tomography angiography, should be considered for patients with blunt thoracic aortic injury undergoing emergency endovascular treatment.</b>			
Class	Level	References	ToE
<b>Iia</b>	<b>C</b>	Jonker <i>et al.</i> (2010), <sup>285</sup> Muhs <i>et al.</i> (2007), <sup>286</sup> Ceja-Rodriguez <i>et al.</i> (2018), <sup>283</sup> García Reyes <i>et al.</i> (2018), <sup>279</sup> Mesar <i>et al.</i> (2022), <sup>287</sup> Bae and Jeon (2024), <sup>281</sup> Gennai <i>et al.</i> (2020) <sup>288</sup>	

**4.1.5.1.2. Left subclavian artery coverage.** Most studies recommend coverage of the left subclavian artery if necessary to obtain a proximal landing zone or to gain better apposition with the lesser curvature of the aortic arch.<sup>289</sup> In a database study of 190 patients treated by TEVAR, DuBose *et al.* reported occlusion of the left subclavian artery in 41% of cases.<sup>260</sup> Although most patients tolerate subclavian artery occlusion well, a significant number develop subclavian steal syndrome or arm claudication and require revascularisation with carotid–subclavian bypass, re-implantation, or use of endovascular techniques. If the patient has absolute contraindications to left subclavian coverage, such as previous coronary artery bypass graft using the left internal mammary artery or evidence of dominant left vertebral artery, an urgent carotid–subclavian bypass should be performed at the time of TEVAR,<sup>278,289–296</sup> or by *in situ* laser fenestration and physician modified endograft technique.<sup>297–299</sup> As yet there are insufficient data to assess the role of the new thoracic branched endografts. Patients with an incomplete circle of Willis, left upper limb dialysis access, or previous extensive aorto-iliac stent graft coverage, compromising the collateral supply to the spinal cord, may also require left subclavian revascularisation.

Recommendation 51			
<b>Routine left subclavian artery revascularisation is not indicated for patients with blunt thoracic aortic injury requiring endovascular stent graft repair with coverage of the left subclavian artery.</b>			
Class	Level	References	ToE
<b>IIia</b>	<b>C</b>	Kritayakirana <i>et al.</i> (2022), <sup>290</sup> Chen <i>et al.</i> (2019), <sup>291</sup> Sepelipour <i>et al.</i> (2011), <sup>292</sup> Rizvi <i>et al.</i> (2009), <sup>293</sup> Matsumura <i>et al.</i> (2010), <sup>294</sup> van der Zee <i>et al.</i> (2019), <sup>278</sup> Romagnoli <i>et al.</i> (2023), <sup>295</sup> Kruger <i>et al.</i> (2022), <sup>296</sup> McBride <i>et al.</i> (2015) <sup>289</sup>	

Recommendation 52			
<b>Left subclavian artery revascularisation is recommended for selected patients with blunt thoracic aortic injury requiring endovascular stent graft repair with coverage of the left subclavian artery and risk of compromised perfusion to brain, heart, or spinal cord.</b>			
Class	Level	References	ToE
<b>I</b>	<b>C</b>	Kritayakirana <i>et al.</i> (2022), <sup>290</sup> Chen <i>et al.</i> (2019), <sup>291</sup> Sepelipour <i>et al.</i> (2011), <sup>292</sup> Rizvi <i>et al.</i> (2009), <sup>293</sup> Matsumura <i>et al.</i> (2010), <sup>294</sup> van der Zee <i>et al.</i> (2019), <sup>278</sup> Romagnoli <i>et al.</i> (2023), <sup>295</sup> Kruger <i>et al.</i> (2022), <sup>296</sup> McBride <i>et al.</i> (2015) <sup>289</sup>	

Recommendation 53			
<b>Delayed left subclavian artery revascularisation should be considered for selected patients with blunt thoracic aortic injury requiring endovascular stent graft repair who develop ischaemic symptoms with coverage of the left subclavian artery.</b>			
Class	Level	References	ToE
<b>Iia</b>	<b>C</b>	Kritayakirana <i>et al.</i> (2022), <sup>290</sup> Chen <i>et al.</i> (2019), <sup>291</sup> Sepelipour <i>et al.</i> (2011), <sup>292</sup> Rizvi <i>et al.</i> (2009), <sup>293</sup> Matsumura <i>et al.</i> (2010), <sup>294</sup> van der Zee <i>et al.</i> (2019), <sup>278</sup> Romagnoli <i>et al.</i> (2023), <sup>295</sup> Kruger <i>et al.</i> (2022), <sup>296</sup> McBride <i>et al.</i> (2015) <sup>289</sup>	

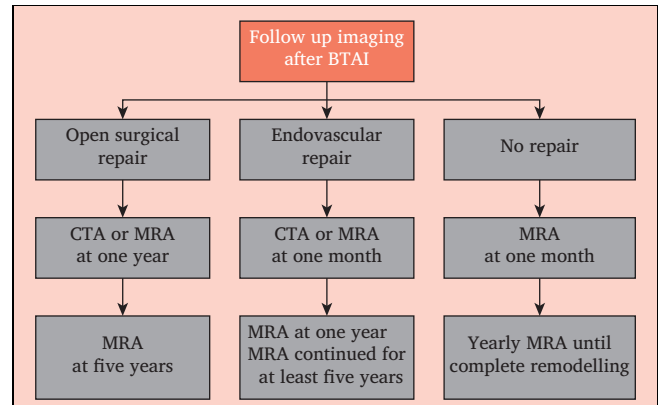
**4.1.5.2. Open surgical repair.** Selected patients with unsuitable aortic anatomy may continue to require OSR. Considerations in selecting OSR include patients anatomically unfavourable for TEVAR with the absence of an adequate proximal landing zone to allow for proper seal of the site of injury by the stent graft. Other anatomical criteria that may preclude TEVAR for BTAI include small (< 7 mm) or diseased iliofemoral vessels, with a risk of access site complications. One of the caveats of OSR in polytrauma patients is the need for systemic anticoagulation with the administration of intravenous heparin.

In recent years, the use of active distal aortic perfusion to reduce the risk of paraplegia has become the standard of care.<sup>300,301</sup> In the AAST1 prospective multi-institutional study, the clamp and sew technique without distal aortic perfusion was performed in 35% ( $n = 73$ ) of all patients undergoing OSR.<sup>231</sup> In these instances, the paraplegia rate was 16.4%. In comparison, in the 134 patients undergoing OSR using distal aortic perfusion, the paraplegia rate was significantly lower at 4.5%. A decade later, a second AAST multi-institutional prospective study (AAST2), including 193

patients subjected to BTAI repair, was published.<sup>49</sup> The incidence of the clamp and sew technique without bypass between 1997 and 2007 had decreased from 35% to 16%. Likewise, the overall incidence of procedure related paraplegia in patients undergoing OSR had fallen significantly from 8.7% to 1.6% ( $p = .001$ ).

These studies have demonstrated that active distal perfusion is superior to passive perfusion in reducing the incidence of procedure related paraplegia. A meta-analysis of mortality and risk of paraplegia following OSR of traumatic aortic rupture in 1492 patients showed an overall post-operative paraplegia rate of 9.9%.<sup>301</sup> Among patients treated with simple aortic cross clamping, the incidence of paraplegia was reported as 19.2%. With passive shunting the incidence of paraplegia was 11.1% and with active perfusion was 2.3%.

In patients who present with free rupture, in settings with limited resources, the clamp and sew technique might be the only option. Primary repair is used only in rare paediatric blunt aortic injuries to avoid coarctation with the graft as the child grows.



**Figure 3.** Suggested follow up imaging after blunt thoracic aortic injury (BTAI). CTA = computed tomography angiography; MRA = magnetic resonance angiography.

needed due to other consequences of implantation of stent grafts (stent graft collapse, hypertension, thrombotic complications) in their vasculature at an early age.<sup>304-313</sup>

Recommendation 54			
Open surgical repair is recommended in selected patients with blunt thoracic aortic injury requiring intervention and with an aortic anatomy unsuitable for a stent graft.			
Class	Level	References	ToE
I	A	Fabian <i>et al.</i> (1997), <sup>231</sup> Demetriades <i>et al.</i> (2008), <sup>49</sup> Estrera <i>et al.</i> (2013) <sup>302</sup>	

Recommendation 55			
Active distal aortic perfusion is recommended to minimise the risk of paraplegia for patients with blunt thoracic aortic injury undergoing open surgical repair.			
Class	Level	References	ToE
I	A	Fabian <i>et al.</i> (1997), <sup>231</sup> Demetriades <i>et al.</i> (2008), <sup>49</sup> Estrera <i>et al.</i> (2013) <sup>302</sup>	

**4.1.6. Long term follow up.** For patients managed non-operatively, the duration of medical therapy and optimal surveillance regimen remain uncertain. For lesions that persist, routine follow up imaging at one month and twelve months and then annually until complete remodelling, is reasonable. Magnetic resonance angiography (MRA) may be a useful alternative to CT, especially in the relatively younger trauma population who may have a more significant risk of malignant disease if lifelong serial CTA studies are required.<sup>303</sup> Finally, there are potential concerns about compliance and follow up among trauma survivors.

The optimal surveillance protocol after open surgical or endovascular repair of BTAI remains undefined (Fig. 3). Patients are usually enrolled in local TEVAR surveillance programmes with different regularities after the first year imaging follow up. Medical follow up of these patients is

Recommendation 56			
Follow up imaging is recommended for patients with blunt thoracic aortic injury who have undergone endovascular stent graft repair, at one month, one year, and thereafter continued for at least five years.			
Class	Level	References	ToE
I	C	Guala <i>et al.</i> (2024), <sup>304</sup> Khoynzhad <i>et al.</i> (2013), <sup>310</sup> Canaud <i>et al.</i> (2015), <sup>306</sup> Spiliotopoulos <i>et al.</i> (2014), <sup>311</sup> Steuer <i>et al.</i> (2015), <sup>312</sup> Gennai <i>et al.</i> (2020), <sup>288</sup> Makalovski <i>et al.</i> (2018) <sup>313</sup>	

Recommendation 57			
Surveillance imaging until aortic remodelling is recommended for patients with blunt thoracic aortic injury who have not undergone thoracic aortic repair.			
Class	Level	References	ToE
I	C	Jacob-Brassard <i>et al.</i> (2019), <sup>238</sup> Arbabi <i>et al.</i> (2022), <sup>240</sup> Soong <i>et al.</i> (2019), <sup>265</sup> Mosquera <i>et al.</i> (2011), <sup>314</sup> Madigan <i>et al.</i> (2022) <sup>315</sup>	

Recommendation 58			
Magnetic resonance angiography is recommended as the preferred imaging method for long term surveillance after blunt thoracic aortic injury.			
Class	Level	References	ToE
I	C	Consensus	

#### 4.2. Blunt injuries to the aortic arch vessels (ascending thoracic aorta and transverse arch, innominate artery, and left common carotid artery)

Rupture of the ascending and transverse aortic arch is uncommon in patients who reach hospital alive, as the mortality rate is high, and exsanguination occurs rapidly. Rupture of the innominate artery is the second most common thoracic arterial injury following blunt aortic trauma. Open repair of aortic arch and great vessel injuries requires a median sternotomy. Injuries to the aortic arch may require hypothermic circulatory arrest and associated antegrade and retrograde cerebral perfusion techniques.<sup>316</sup> Endovascular solutions with stent graft for injuries of the innominate artery or left CCA have been described, mostly as case reports in haemodynamically stable patients.<sup>317,318</sup> Non-operative treatment with antiplatelet therapy for minor injuries to these arteries (ESVS Grade 1) seems reasonable, but the evidence is lacking.

##### Recommendation 59

The treatment choice of open surgical or endovascular repair of innominate artery or proximal left common carotid artery injury (ESVS Grade 2 and 3) should be considered based on haemodynamic status, anatomy, and concomitant injuries.

Class	Level	References
Ila	C	Consensus

#### 4.3. Penetrating thoracic aortic injury

Penetrating thoracic aortic injury (PTAI) is less frequent than BTAI, with only one large retrospective cohort study using the National Trauma Data Bank.<sup>319</sup> In this series, a total of 2 714 patients with PTAI and 14 037 patients with BTAI were reported. Compared with BTAI, patients with PTAI were younger, more often male, and more likely to arrive without signs of life (27.6% vs. 7.5%;  $p < .001$ ). Patients with PTAI were more likely to have injuries to the oesophagus, diaphragm, and heart compared with those with BTAI. Patients with PTAI were less likely to undergo endovascular repair (5.8% vs. 30.5%) or OSR (3.0% vs. 4.2%) than patients with BTAI. While the large majority of patients with PTAI died before arrival or in the emergency department, the in hospital mortality rate among those who survived the first day was still 43%. In another large registry of 1 186 patients from South Africa, PTAI had a high mortality rate of 30% for patients with stab wounds and 52% for those with gunshot wounds.<sup>320</sup>

In unstable patients with PTAI, emergency room thoracotomy has generated controversy and is best applied to patients sustaining penetrating cardiac injuries who arrive at trauma centres with signs of life, pupillary response, carotid pulse, and cardiac electrical activity with the aim of alleviating pericardial tamponade, repairing potential cardiac injuries, and providing open cardiac massage.<sup>321</sup>

#### 4.4. Blunt and penetrating subclavian artery injury

Pre-operative CTA for incision planning to obtain proximal control of subclavian artery injuries is valuable. The standard open exposure for proximal injuries to the right subclavian

artery is via a median sternotomy and a right cervical or supraclavicular extension. Proximal control of proximal left sided subclavian injuries is obtained via a median sternotomy. A separate left supraclavicular incision can be used for distal control. A hybrid approach combining open and endovascular techniques is an alternative for proximal control that may avoid the need for a sternotomy in selected patients.

Endovascular approaches to the repair of subclavian arterial injuries have been described both in blunt and penetrating trauma.<sup>53,322-325</sup> In appropriately selected patients, stent graft placement is associated with improved outcomes for injuries in these areas that can be challenging open exposures. Branco *et al.* found that endovascular treatment of subclavian injuries was associated with lower in hospital mortality and surgical site infection rates than open repair.<sup>53</sup> A report of a large cohort of patients from the National Trauma Data Bank comparing open and endovascular repair found that mortality was improved with endovascular repair across a wide range of thoracic vascular injuries.<sup>10</sup> Additional literature supports these findings, but with a paucity of long term follow up.<sup>326</sup> In one recent small report ( $n = 40$ ), primary endovascular stent graft repair patency was only 42% after five years, but no re-interventions were needed because occlusions did not cause symptoms.<sup>327</sup> The PROOVIT registry is capturing data in a multicentre, multinational fashion to better define the optimal management and follow up of these injuries.<sup>2</sup>

##### Recommendation 60

Endovascular stent graft repair should be considered the preferred treatment modality for patients with subclavian artery injury (ESVS Grade 2 and 3) requiring operative treatment.

Class	Level	References	ToE
Ila	B	Branco <i>et al.</i> (2016), <sup>53</sup> Zambetti <i>et al.</i> (2022), <sup>328</sup> DuBose <i>et al.</i> (2012), <sup>325</sup> Waller <i>et al.</i> (2017), <sup>329</sup> Hanif <i>et al.</i> (2023) <sup>330</sup>	

### 5. ABDOMINAL VASCULAR TRAUMA

Major abdominal vascular injuries are in general rare, primarily associated with penetrating mechanisms, and carry a high mortality rate.<sup>331-333</sup> The most frequently injured abdominal vessels are the aorta, superior mesenteric artery (SMA), iliac arteries, renal arteries, inferior vena cava (IVC), portal vein, and iliac veins.<sup>13,334,335</sup> These vascular injuries are most often combined with other abdominal injuries, liver and bowel injuries in 25 – 35%, and less commonly with splenic, pancreatic, and genitourinary injuries (10 – 20%).<sup>332,336</sup>

#### 5.1. Clinical presentation

Abdominal vascular injuries typically present with clinical signs of bleeding due to intra-abdominal or retroperitoneal blood loss. Patients with ongoing haemorrhage require massive blood transfusion and fast life saving interventions for haemorrhage control.<sup>331</sup> Patients with major vascular injuries may present in cardiopulmonary arrest and require resuscitative thoracotomy, both of which correlate with poor survival.<sup>334,337</sup>

However, in some cases, patients present with only indirect signs with a consequent risk of delayed diagnosis. Thirty percent of patients with abdominal arterial injuries are haemodynamically stable on admission.<sup>338</sup> When bleeding has remained contained by retroperitoneal tamponade, patients with IVC, iliac, and other retroperitoneal vascular injuries may present in a haemodynamically stable condition.<sup>339</sup> The patient's haemodynamic status determines whether to perform immediate surgical exploration or to proceed with diagnostic imaging.

### 5.2. Diagnostic imaging

CTA is the primary imaging investigation for abdominal vascular injuries and abdominal trauma in general.<sup>95,340,341</sup> Arterial phase imaging provides optimal visualisation of the arterial structures and bleeding and, in combination with portal venous phase imaging, can help differentiate between arterial and venous haemorrhage.<sup>342,343</sup>

### 5.3. Intra-operative management of retroperitoneal haematoma

Patients in shock with ongoing haemorrhage and suspicion of major abdominal injuries should be taken immediately to the operating room for exploration, bleeding control, and resuscitation using a major haemorrhage protocol.<sup>344</sup>

Recommendation 61			
Immediate surgical exploration and haemorrhage control are recommended for patients in shock with ongoing bleeding and suspicion of major abdominal vascular injury.			
Class	Level	References	ToE
I	C	Sorrentino <i>et al.</i> (2012) <sup>344</sup>	

Damage control principles should be used in patients with active haemorrhage. If there are significant amounts of free blood intraperitoneally at trauma laparotomy, resuscitative packing should be performed after evacuation of blood and clots, and bowel evisceration. If major haemorrhage continues despite peritoneal packing, or the patient arrests when the abdominal cavity has been opened, the aorta should be compressed at the hiatus. If cardiac arrest occurs before the abdominal cavity is entered, an anterolateral emergency thoracotomy should be performed for thoracic aortic compression.

The management of retroperitoneal haematomas is low in evidence but has evolved from trauma experience over decades and observational studies.<sup>345–347</sup> The approach to retroperitoneal haematomas has traditionally depended on the haemodynamic status of the patient, mechanism of injury, location of the retroperitoneal haematoma, and the presence of associated injuries.<sup>332,345</sup> Management of retroperitoneal haematomas related to the zone classification was developed prior to widespread CTA availability and the increased use of endovascular techniques. Retroperitoneal haematomas are not limited by zone boundaries.

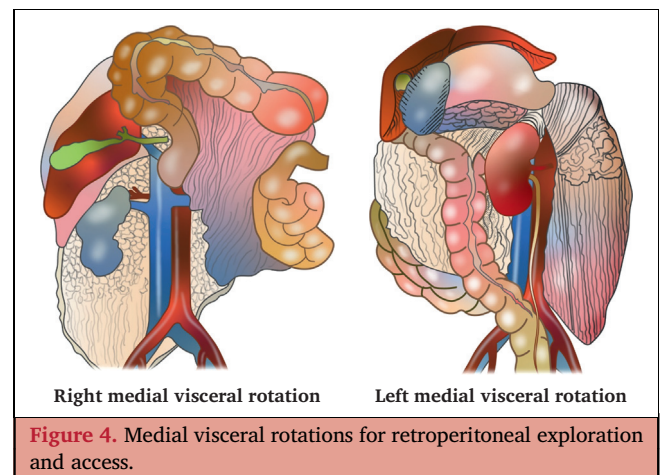
Patient haemodynamic status and the stability of the retroperitoneal haematoma will determine the management approach. Haemodynamic stability and a retroperitoneal

haematoma not expanding, pulsatile, or actively bleeding (stable retroperitoneal haematoma) provide an opportunity for further investigation with CTA to direct management. In patients who are haemodynamically unstable or have an unstable retroperitoneal haematoma (expanding, pulsatile, or actively bleeding), surgical exploration of the retroperitoneal haematoma during trauma laparotomy is needed. Where expertise to explore the retroperitoneum is not available, some haematomas may be temporarily controlled with packing techniques, to await arrival of expertise or transfer to another institution. Where packing does not control substantial arterial injuries, an attempt at exploration and control must be made. Pre-peritoneal packing of unstable intrapelvic haematoma associated with pelvic fracture can be a bridge to endovascular control by embolisation.<sup>332,345</sup> Where packing does not stabilise the retroperitoneum, exploration for internal iliac artery ligation may be required.

Recommendation 62		
Surgical exploration of retroperitoneal haematomas during trauma laparotomy is recommended in patients who are haemodynamically unstable OR who have an unstable retroperitoneal haematoma (expanding, pulsatile, or actively bleeding).		
Class	Level	References
I	C	Consensus

Recommendation 63		
A non-exploratory approach of retroperitoneal haematomas during trauma laparotomy, with subsequent computed tomography angiography imaging, is recommended for patients who are haemodynamically stable AND have a stable retroperitoneal haematoma (not expanding, not pulsatile, and not actively bleeding).		
Class	Level	References
I	C	Consensus

Surgical exploration of the retroperitoneum for traumatic injuries is principally via right or left medial visceral rotation (Fig. 4). Of these, right visceral rotation provides access to



the suprarenal and infrarenal IVC, aorta to the base of the SMA, all iliac vessels, and the right renal vessels and kidney. The right rotation can be extended proximally to access the retrohepatic and suprahepatic IVC. Left medial visceral rotation is reserved for injuries to the coeliac and mesenteric portions of the aorta but also the left renal vessels and kidney.

Pelvic haematoma exploration, when required, usually starts over the common iliac artery bifurcation so the origin of the internal iliac artery can be controlled.

Recommendation 64		
Non-operative management with surveillance and antithrombotic therapy is recommended for patients without ongoing bleeding and blunt minor abdominal aortic, iliac, renal, or superior mesenteric artery injuries (ESVS Grade 1) on computed tomography angiography.		
Class	Level	References
I	C	Consensus

#### 5.4. Abdominal aorta

Abdominal aortic injuries are rare, and more severe injury grades are associated with a considerable mortality rate.<sup>348,349</sup>

**5.4.1. Non-operative management.** Several studies have demonstrated high success rates with the non-operative management (serial imaging for surveillance and blood pressure optimisation) of appropriately selected blunt abdominal aortic injuries. In a Western Trauma Association (WTA) multicentre study (113 patients, 0.03% of all blunt trauma patients, presenting with blunt abdominal aortic injury at 12 major trauma centres), 35.4% of injuries were managed non-operatively with a low failure rate.<sup>348</sup> The majority of those selected presented without aortic contour abnormalities (ESVS Grade 1) (89.5% of intimal tears and 44.7% of large intimal flaps). In addition, one third of pseudoaneurysms (ESVS Grade 2) were also managed non-operatively.

In a single centre study from a high volume trauma centre, selective non-operative management was employed in eight blunt abdominal aortic injuries, with only one subsequent death attributed to aortic injury.<sup>350</sup> Among patients surviving to discharge, no patient had progression of injury on outpatient follow up or required additional intervention.<sup>350</sup> A similar single centre review from the Shock Trauma Medical Centre (Baltimore, MD, USA) found that among 17 patients with blunt abdominal aortic injury, minimal aortic injuries could be safely observed without major complications.<sup>351</sup> In that report, all patients underwent repeat imaging during initial hospitalisation and after discharge. No patients sustained malperfusion, death, or progression of injury during index admission. Only one patient progressed to a pseudoaneurysm eight months after the initial injury.<sup>351</sup>

**5.4.2. Open surgical repair.** OSR is usually performed when aortic injuries are encountered at the time of initial exploratory laparotomy and is the most common repair type for

penetrating injuries.<sup>348,350</sup> It is also an option after blunt occlusive aortic trauma (ESVS Grade X), especially in the younger population, encountered after CTA investigation. The opportunities for primary repair are probably limited in most cases. The most common reported repair types are reconstruction with an aortic tube or bifurcated graft.<sup>350</sup> Synthetic graft is a reasonable graft material to use in the emergency situation with or without concomitant bowel injury.

Recommendation 65			
Open surgical repair is recommended as first line treatment for patients with blunt or penetrating abdominal aortic injury with free haemorrhage and haemodynamic instability (ESVS Grade 3).			
Class	Level	References	ToE
I	C	Shalhub <i>et al.</i> (2014), Charlton-Ouw <i>et al.</i> (2016) <sup>350</sup>	

Recommendation 66		
Synthetic graft material is recommended for aortic reconstruction in emergency situations with or without concomitant bowel injury.		
Class	Level	References
I	C	Consensus

**5.4.3. Endovascular repair.** Data examining the utility of endovascular treatment of abdominal aortic injuries are very limited. However, extrapolating from more robust data at the thoracic aortic and iliac artery locations, endovascular techniques may pose benefit to the patient with regard to the outcome when amenable anatomy is encountered.

In a WTA study ( $n = 113$ ), 15% of blunt abdominal aortic injuries underwent endovascular repair.<sup>348</sup> A variety of stents and stent grafts were used. All patients in this group were discharged alive after a median length of stay of 12 days. An additional five patients employed endovascular therapies as adjuncts to either open or hybrid repair or to facilitate embolisation of associated injury to abdominal arterial branch injuries.<sup>348</sup> Dayama *et al.* completed a review of the National Trauma Data Bank from 2008 to 2012 for patients sustaining abdominal aortic injury.<sup>352</sup> They found that 28.0% (91/325) underwent endovascular repair of these injuries. After adjustment for injury characteristics and haemodynamic status, the open repair cohort had 6.6 times higher odds of death (95% CI 3.25 – 13.33;  $p < .001$ ) compared with the endovascular repair cohort.

As with thoracic aortic endograft sizing, available data suggest that caution should be exercised when making stent graft size selection based on initial trauma CT scans. Several studies have shown that volume depletion in trauma patients may contribute to underestimation of vessel diameter and stent graft size needed on these initial scans.<sup>283,353</sup> A repeat CTA could be valuable for stent graft planning if the patient becomes normovolaemic.

Recommendation 67			
Endovascular stent graft repair should be considered for haemodynamically stable patients and abdominal aortic injury with external contour abnormality such as a pseudoaneurysm (ESVS Grade 2).			
Class	Level	References	ToE
Ia	C	Shalhub <i>et al.</i> (2014), <sup>348</sup> Dayama <i>et al.</i> (2017) <sup>352</sup>	

Recommendation 68			
Stent graft oversizing between 20% and 30% should be considered when imaging was performed during hypotension for patients with abdominal aortic injury undergoing emergency endovascular treatment.			
Class	Level	References	ToE
Ia	C	Jonker <i>et al.</i> (2010), <sup>353</sup> Ceja-Rodriguez <i>et al.</i> (2018) <sup>283</sup>	

### 5.5. Iliac arteries

Traumatic iliac vessel injuries, usually caused by a penetrating mechanism, are relatively rare with an incidence of < 2% of all vascular trauma and reported mortality rates of 24 – 80%.<sup>337,354</sup> The high mortality rate of iliac vessel injuries has frequently been attributed to the absence of retroperitoneal tamponade, which can lead to fast and massive haemorrhage and irreversible shock.<sup>339</sup> The common iliac artery is the most frequently injured iliac artery, with an incidence of 40%, while the internal and external iliac arteries account for 30% each.

**5.5.1. Open surgical repair.** Ruptured iliac arteries (ESVS Grade 3) encountered at damage control laparotomy can be very challenging given their anatomic location and the large associated retroperitoneal haematoma.<sup>334</sup> Patients with severe injury and haemodynamic instability may be candidates for temporary vascular shunting, which has been found to be safe, with low rates of associated complications and death.<sup>355</sup> The common and external iliac arteries should be repaired primarily if possible, and when there is significant destruction of the vessel wall, reconstruction can be accomplished with a synthetic interposition graft.

Mortality rates in patients undergoing ligation of the common or external iliac arteries are documented to be very high, ranging from 30% to 90%, reflecting the challenging nature of these injuries as well as the need to restore distal flow as an emergency. Other complications include amputation (as high as 54% and 47% for the common and external iliac arteries, respectively).<sup>356</sup> One internal iliac artery can be ligated without clinical consequence. Ligation of both internal iliac arteries can lead to pelvic and or ischaemic bowel complications, and ligation of both vessels is rarely indicated, even *in extremis*.

Recommendation 69			
Primary surgical repair, synthetic interposition graft reconstruction, or vascular shunting is recommended for common or external iliac artery injury (ESVS Grade 3) discovered during emergency laparotomy.			
Class	Level	References	ToE
I	C	Consensus	

**5.5.2. Endovascular repair.** Endovascular iliac artery injury (ESVS Grade 2) repair with stent graft, if anatomically suitable, has been reported as a potentially less invasive alternative to open surgery with significantly lower rates of in hospital death, sepsis, and surgical site infection.<sup>357,358</sup> Stent graft repair of ESVS Grade 3 injuries can be considered depending on the availability of interventional resources, but ESVS Grade X is most commonly treated by open repair. The utility of embolisation of bleeding internal iliac arteries and branches after major pelvic trauma is well documented.<sup>1</sup> Initial management includes resuscitation, mechanical stabilisation of the pelvis, and identification and treatment of any extrapelvic bleeding sources. Pelvic angiography and embolisation will benefit the cohort of patients with clinical signs of bleeding and arterial extravasation or indirect signs of bleeding (pseudoaneurysm, abrupt cutoff of vessels, AVF, and vascular spasm) seen on CTA.

Recommendation 70			
Endovascular stent graft repair should be considered for ESVS Grade 2 or 3 common or external iliac artery injury.			
Class	Level	References	ToE
Ia	C	Kufner <i>et al.</i> (2015), <sup>357</sup> Ruffino <i>et al.</i> (2020) <sup>358</sup>	

Recommendation 71			
Endovascular treatment with embolisation is recommended for patients with pelvic injury and clinical signs of ongoing bleeding or imaging showing extravasation from the internal iliac artery or its branches.			
Class	Level	References	ToE
I	B	Velmahos <i>et al.</i> (2000), <sup>359</sup> Fu <i>et al.</i> (2012), <sup>360</sup> Bonde <i>et al.</i> (2020) <sup>361</sup>	

### 5.6. Mesenteric arteries (superior and inferior mesenteric artery, coeliac artery)

An analysis of the US Trauma Quality Improvement Program identified 1403466 patients where 1730 had a single visceral artery injury with 699 (40.4%) involving the coeliac artery, 889 (51.4%) the SMA, and 142 (8.2%) the inferior mesenteric artery.<sup>362</sup> There is a paucity of studies on the management strategy.

**5.6.1. Operative management.** In a damage control situation with injury to the SMA, primary repair is the best option, but if not possible a temporary vascular shunt has been suggested, although these can be challenging to place depending on the level of injury.<sup>362,363</sup> There is insufficient contemporary literature on the open surgical or endovascular management of trauma to the mesenteric arteries. Operative surgical management (ESVS Grade 2, 3, or X) may consist of primary repair, ligation, interposition graft, extra-anatomic bypass, or the insertion of a temporary vascular shunt.<sup>364</sup> If there is suspicion of concomitant pancreatic injury, the graft can be placed away from the pancreas with proximal anastomosis from the infrarenal aorta to the SMA.<sup>364</sup> There are small case series that have demonstrated the use of stent grafts (ESVS Grade 2, 3, or X).<sup>362,363</sup> For the inferior mesenteric artery, ligation is possible due to the mesenteric collateral circulation.

Recommendation 72			
Endovascular stent or stent graft repair may be considered for ESVS Grade X superior mesenteric artery injury to achieve early restoration of bowel perfusion.			
Class	Level	References	ToE
I <b>ib</b>	C	Maithel <i>et al.</i> (2020), <sup>362</sup> Evans <i>et al.</i> (2021) <sup>363</sup>	

Recommendation 73			
Ligation is recommended for treatment of inferior mesenteric artery injury.			
Class	Level	References	ToE
I	C	Consensus	

**5.6.2. Non-operative management.** Non-operative treatment with antithrombotic therapy seems reasonable for ESVS Grade 1 injuries, but the evidence is lacking.

**5.7. Renal arteries**

Blunt renal trauma constitutes 90% of all renal trauma with only 5% involving the renal vasculature.<sup>365–367</sup> The renal artery is susceptible to injury during rapid deceleration owing to the mobility of the kidneys. This may cause a stretch lesion with subsequent intimal tear or intramural haematoma (ESVS Grade 1), and possibly arterial thrombosis (ESVS Grade X).<sup>368–371</sup> Studies indicate that renal trauma may induce irreversible damage to renal vascular integrity, resulting in both short and long term sequelae such as high blood pressure and kidney failure.<sup>372,373</sup>

**5.7.1. Non-operative management.** Unilateral main arterial injuries (ESVS Grade 1) or arterial thrombosis (ESVS Grade X) are normally managed non-operatively. A devascularised kidney diagnosed on CTA is unlikely to benefit

from stenting as the warm ischaemia time will always be too long resulting in irreversible renal damage.<sup>367,374–376</sup>

Recommendation 74			
Revascularisation of a devascularised unilateral kidney identified on computed tomography angiography is not recommended.			
Class	Level	References	ToE
III <b>b</b>	C	Ouriel <i>et al.</i> (1987), <sup>374</sup> Hass <i>et al.</i> (1998), <sup>375</sup> Jawas <i>et al.</i> (2008) <sup>376</sup>	

**5.7.2. Open surgical and endovascular management.** Arterial injuries identified peri-operatively can be repaired primarily or reconstructed with a graft.<sup>377,378</sup> Overall, the degree of renal vascular injury and the presence of a normal sized uninjured contralateral kidney as well as the physiological status and haemodynamic stability of the patient will dictate if a nephrectomy is the best option. Renal artery repair has been reported in patients with a solitary kidney or bilateral injuries in an attempt to avoid permanent renal failure.<sup>367,379</sup>

Recommendation 75			
Open or endovascular renal artery repair should be considered for haemodynamically stable patients and ESVS Grade 3 renal artery injury.			
Class	Level	References	ToE
I <b>ia</b>	C	Consensus	

Recommendation 76			
Ligation of the renal artery, with or without simultaneous nephrectomy, is recommended in a haemodynamically unstable patient with severe renal artery injury (ESVS Grade 3).			
Class	Level	References	ToE
I	C	Santucci <i>et al.</i> (2005), <sup>379</sup> Morey <i>et al.</i> (2021), <sup>367</sup> Knudson <i>et al.</i> (2000) <sup>377</sup>	

Endovascular renal artery stent graft or stent placement in rupture cases (ESVS Grade 3), pseudoaneurysm (ESVS Grade 2), or flow limiting dissections (ESVS Grade 1) has been described, while for the segmental or cortical renal arterial tracts associated with focal bleeding, embolisation is suggested as the best option.<sup>380</sup>

A summary of the general approach to the treatment of abdominal arterial injuries is provided in [Table 11](#).

Recommendation 77			
Endovascular stent graft repair should be considered for haemodynamically stable patients with ESVS Grade 2 injury (e.g., pseudoaneurysm) of the renal artery.			
Class	Level	References	ToE
I <b>ia</b>	C	Liguori <i>et al.</i> (2021) <sup>380</sup>	



**Table 11.** Abdominal arterial injuries: summary of general treatment approaches. Specific management should follow the recommendations above, individualised to the patient, clinical environment, and available resources.

ESVS Grade	Description	Management		
		Common and external iliac arteries	Superior mesenteric artery	Renal artery
1	Partial wall injury, normal external wall contour	Antithrombotic or single antiplatelet therapy + surveillance	Antithrombotic or single antiplatelet therapy + surveillance	Antithrombotic or single antiplatelet therapy + surveillance
2	Complete wall injury, abnormal external wall contour, pseudoaneurysm	Consider stent graft	Consider stent graft	Consider stent graft
3	Complete wall injury, uncontained haemorrhage	Open surgical repair, shunt, or stent graft	Open surgical repair, shunt or ligate, or stent graft	Stable haemodynamics: consider operative repair Unstable haemodynamics: renal artery ligation
X	Occlusion	Open surgical repair (interposition graft) Temporarily shunt if required	Non-operative. Endovascular stent or stent graft repair if inadequate collateralisation or salvageable bowel ischaemia	Non-operative unless single kidney or bilateral renal artery occlusions and salvageable kidney. No revascularisation of a devascularised unilateral kidney

**Recommendation 78**

Open or endovascular renal artery repair is recommended for patients with bilateral ESVS Grade 2, 3, or X renal artery injuries or if there is a solitary salvageable kidney.

Class	Level	References	ToE
I	C	Santucci <i>et al.</i> (2005), <sup>379</sup> Knudson <i>et al.</i> (2000) <sup>377</sup>	

**Recommendation 80**

Non-operative management with close observation and follow up imaging should be considered in haemodynamically stable patients with inferior vena cava injury and a stable retroperitoneal haematoma (not expanding and not actively bleeding).

Class	Level	References	ToE
IIa	C	Pinto <i>et al.</i> (2023), <sup>386</sup> Choi <i>et al.</i> (2023) <sup>387</sup>	

**Recommendation 79**

Vein ligation is recommended for abdominal venous injury if repair is not easily achievable.

Class	Level	References	ToE
I	C	Balachandran <i>et al.</i> (2020), <sup>381</sup> Stonko <i>et al.</i> (2023), <sup>52</sup> Navsaria <i>et al.</i> (2005), <sup>382</sup> Matsumoto <i>et al.</i> (2018), <sup>383</sup> Howley <i>et al.</i> (2019), <sup>335</sup> Asensio <i>et al.</i> (2007), <sup>364</sup> Asensio <i>et al.</i> (2003) <sup>337</sup> Ksycki <i>et al.</i> (2012), <sup>384</sup> Magee <i>et al.</i> (2018) <sup>339</sup>	

**5.8. Inferior vena cava and major abdominal veins**

**5.8.1. Inferior vena cava.** IVC injuries are associated with mortality rates ranging from 30% to 70%, depending on the anatomical level, with infrarenal injuries having a better outcome.<sup>52,381,385</sup>

**5.8.1.1. Non-operative management.** A few case reports describe non-operative management of blunt isolated IVC injuries in haemodynamically stable patients with close monitoring and observation.<sup>386-388</sup>

**5.8.1.2. Operative management.** Minor IVC injuries can be repaired with simple continuous sutures where some degree of stenosis is acceptable. Larger defects can temporarily be controlled with a shunt or can be ligated.

Due to deranged physiology and concomitant injuries, an open surgical damage control approach frequently includes IVC ligation with an acceptable outcome.<sup>52,381-383</sup> In a systematic review, ligation of IVC injuries was associated with an increased mortality rate compared with repair, but not in the subset of patients with infrarenal IVC injury.<sup>389</sup> In a retrospective analysis from the National Trauma Data Bank, IVC ligation was not independently associated with death or lower extremity amputation, but it was associated with acute kidney injury and the need for fasciotomy.<sup>390</sup> A propensity score matching analysis demonstrated that IVC ligation is not superior to repair in decreasing the mortality rate in patients with IVC injury.<sup>383</sup> However, both these studies lacked data on anatomic level of injury.<sup>383,390</sup> It is also possible that modern database reports may benefit from advances in critical care and use of damage control techniques.<sup>389</sup>

For retrohepatic injuries, packing of the liver onto the posterior abdominal wall is the procedure of choice. If bleeding cannot be controlled with packing, direct

visualisation and repair will be required, although mortality rates from such injuries are very high. Atriocaval shunting has been suggested as a modality for these injuries, but evidence supporting its benefit is lacking.<sup>391,392</sup> The reported literature demonstrates a poor outcome in patients who required atriocaval shunt, reflecting the high burden of injury and the relative limited use.<sup>392</sup>

To reduce surgical morbidity in trauma patients, placement of a stent graft for the venous injury may represent an alternative to open surgery. In a recent study from the PROOVIT database, < 2% of IVC injuries were treated endovascularly with no increase in overall survival.<sup>52</sup> In selected cases of injury to the IVC and iliac veins, the use of stent grafts can be successful for urgent bleeding control with good short term results. Smeets *et al.* have reported a series of 35 patients injured through trauma or with iatrogenic injury during surgery treated with various stent grafts.<sup>393</sup> In all patients, the treatment was technically successful and the 30 day mortality rate for the entire series was 2.9%, but long term outcome data are lacking.<sup>393</sup> Stent grafts may offer an alternative to IVC injury management, although their role as a temporary bridge or as definitive treatment needs to be further defined.

Recommendation 81			
Atriocaval shunting is not indicated in the management of inferior vena cava injuries.			
Class	Level	References	ToE
IIIa	C	Sullivan <i>et al.</i> (2010), <sup>391</sup> Zargaran <i>et al.</i> (2020) <sup>392</sup>	

**5.8.2. Iliac veins.** Iliac vein injury is often associated with iliac artery injury and surgical access may be restricted by the overlying artery.<sup>337,339</sup> Injuries to the common and external iliac veins can be repaired primarily.<sup>384</sup> In a retrospective review, iliac vein ligation was associated with a higher mortality rate than repair (OR 2.2, 95% CI 1.08 – 4.66), but no statistically significant difference in deep venous thrombosis, pulmonary embolism, fasciotomy, or amputation.<sup>339</sup> These data supported that repair of iliac vein injuries was preferable to ligation whenever feasible. Ligation of the iliac veins is suggested in the literature for complex venous injuries or haemodynamically unstable patients.<sup>337,384</sup> Previous studies have shown that ligation of the common or external iliac vein is tolerated with few adverse sequelae and similar rates of complications compared with repair.<sup>337,384</sup> There are no data supporting venous reconstruction using interposition grafts in the multiple trauma patient.

**5.8.3. Portal vein and superior mesenteric vein.** Although uncommon, injuries to the portal vein (PV) and superior mesenteric vein (SMV) are associated with mortality rates between 40% and 72%.<sup>334,364,394–397</sup> As the PV and SMV are located at the root of the mesentery, concomitant injuries to the IVC, pancreas, liver, and or gastrointestinal tract are classically encountered and will influence treatment options. Injuries can be repaired with continuous sutures or controlled temporarily by inserting a shunt.

In a study by Howley *et al.*, 24 patients with portal ( $n = 7$ ) and superior mesenteric ( $n = 15$ ) vein injuries (two patients had combined injuries) were reported with a mortality rate of 62% (15/24).<sup>335</sup> There were 17 patients who received direct suture venorrhaphy, including all nine survivors. The study concluded that no firm conclusion could be drawn regarding techniques for repair. Whether venorrhaphy, ligation, shunting, or bypass is used first, salvage techniques are highly unlikely to succeed if the first attempt fails.<sup>335</sup> Ligation of the PV and SMV can cause venous congestion and ischaemia of the midgut and is associated with mortality rates as previously described, but ligation is reasonable to perform in a damage control situation of a haemodynamically compromised patient. Transjugular intrahepatic portosystemic shunt (TIPS) is a promising option to treat portal hypertension at a later stage.<sup>398</sup> The inferior mesenteric vein can be ligated more liberally.

**5.8.4. Renal veins.** Literature of the incidence, morphologies, management, and outcomes of patients with renal vein injuries on which to base treatment recommendations is virtually non-existent. In general, renal vein injuries are repaired by venorrhaphy and, if this is not possible due to anatomy or physiology, ligation is suggested. Ligation of the left renal vein near the IVC is usually well tolerated because of venous collateral outflow. However, this collateral outflow does not exist for the right renal vein, and ligation here usually results in loss of right kidney function.

## 6. EXTREMITY VASCULAR TRAUMA

The lower and upper extremities are the most common anatomic locations for civilian, military, and terrorism related vascular injuries.<sup>2,14,21,24</sup> The extremities are particularly susceptible to vascular injury both from blunt and penetrating trauma owing to the relatively unprotected anatomic position of the vasculature, proximity to the long bones, and susceptibility of the elbow and knee joints to fracture or dislocation. In many patients there is concomitant injury to the nerves. This may hinder diagnosis of the vascular injury and is of foremost importance for long term functional outcomes. The risk of amputation after extremity vascular trauma is substantial, and long term results are often disappointing with many patients experiencing chronic pain, motor and sensory deficits, and difficulties with activities of daily living.<sup>141,399,400</sup> Limb salvage and good functional outcome rates are closely related to time to revascularisation, and restoration of arterial flow must be prioritised in managing extremity vascular injuries.

### 6.1. Clinical presentation

**6.1.1. Physical examination.** Careful physical examination guides diagnostic investigations and treatment decisions. In extremity vascular trauma, active haemorrhage (external bleeding, expanding haematoma) or absent palpable pulse are indicators of clinically significant damage to a vascular structure (ESVS Grade 3 or X).<sup>93,400–402</sup> However, the absence of these signs does not exclude

vascular injury. Clinical examination of the injured and any non-injured extremity is essential to specifically evaluate the limb for any haemorrhagic or ischaemic signs, e.g., absence of easily palpable peripheral pulses, delayed capillary refill, pallor, paraesthesia, pain, or paralysis.<sup>96</sup> Importantly, accompanying nerve injury, which is particularly prevalent in elbow or knee dislocations, may hinder evaluation of the vascular status. The presence of an easily palpable peripheral pulse in both the upper and lower extremities is crucial, as it can rule out significant vascular injuries, as shown in several large retrospective studies.<sup>93,400–402</sup> Conversely, if peripheral pulses are not easily palpable, prompt imaging must be performed to rule out arterial injury.

Recommendation 82			
Careful clinical vascular examination is recommended in all patients with extremity trauma to identify potential haemorrhagic or ischaemic vascular injuries.			
Class	Level	References	ToE
I	C	Abou-Sayed <i>et al.</i> (2002), <sup>400</sup> Inaba <i>et al.</i> (2011), <sup>93</sup> Joseph <i>et al.</i> (2021), <sup>401</sup> Le Roux <i>et al.</i> (2021) <sup>402</sup>	

**6.1.2. Ankle brachial index.** Several studies have explored the usefulness of the ankle brachial index (ABI) and have reported conflicting results regarding its ability to rule out significant arterial injuries in both blunt and penetrating trauma.<sup>403–406</sup> Its added value compared with a thorough physical examination conducted by an experienced physician is limited.<sup>93,400–402</sup> Moreover, obtaining an accurate ABI requires time and skill.

Recommendation 83			
An ankle brachial index is not indicated to diagnose or rule out vascular injury in patients with extremity trauma.			
Class	Level	References	ToE
IIIa	C	Abou-Sayed <i>et al.</i> (2002), <sup>400</sup> Inaba <i>et al.</i> (2011), <sup>93</sup> Joseph <i>et al.</i> (2021), <sup>401</sup> Le Roux <i>et al.</i> (2021) <sup>402</sup>	

## 6.2. Diagnostic imaging

CTA should be performed in all patients with suspected vascular trauma to the extremities, following a careful physical examination. CTA has high sensitivity and specificity for detecting arterial injury.<sup>94</sup> It is important to note that imaging should be conducted promptly without causing any delay in treatment. In certain urgent cases, immediate treatment should be administered without prior imaging.<sup>407</sup>

If pre-operative imaging is not feasible, intra-operative angiography can be a beneficial diagnostic and to decide an open or endovascular approach. The role of magnetic resonance imaging (MRI) and DUS in assessing extremity

vascular trauma has not been investigated extensively. However, in cases where pseudoaneurysms or arteriovenous fistulae are suspected, DUS may have a potential role to play.

Recommendation 84			
Immediate computed tomography angiography is recommended as the primary imaging modality in patients with extremity injury where significant vascular injury cannot be ruled out by clinical vascular examination (palpable peripheral pulses).			
Class	Level	References	ToE
I	C	Adibi <i>et al.</i> (2014), <sup>86</sup> Branco <i>et al.</i> (2015), <sup>89</sup> Jens <i>et al.</i> (2013) <sup>94</sup>	

## 6.3. Management

**6.3.1. Time to repair.** In patients with limb ischaemia secondary to major arterial injury (ESVS Grade X), the classic teaching has been that limb salvage is possible up to six hours from onset (which approximates to the time of injury). This is largely based on clinical experience in the management of acute limb ischaemia secondary to thromboembolic disease or atherosclerosis. Applying this time threshold to extremity vascular trauma in a meta-analysis of over 3 000 patients undergoing revascularisation demonstrated that duration of ischaemia exceeding six hours was an independent prognostic factor for amputation.<sup>408</sup> However, in a recent US national registry study of nearly 4 500 patients with extremity vascular trauma, the amputation rate was significantly lower in those who had a time within 60 minutes from injury to arrival in the operating room for revascularisation (33/554) compared with those who arrived after one to three hours (255/2 186) and three to six hours (171/1 275) (6.0% vs. 11.7% and 13.4%, respectively).<sup>107</sup> Time to revascularisation remained a significant predictor of limb salvage in multivariable analysis adjusting for injury severity, mechanism of injury, and age. Similarly, data from a US/UK military dataset found a linear relationship between ischaemic time and successful limb salvage with a 10% reduction in the probability of successful limb salvage for every hour delay from injury to revascularisation.<sup>409</sup> The probability of limb salvage was 86% when ischaemia time was within one hour. The presence of shock more than doubled the risk of failed limb salvage. There is similar evidence in upper limb vascular injuries with data from over 5 000 arterial repairs finding a significant decrease in the rate of amputation when patients underwent revascularisation within 90 minutes of injury.<sup>410</sup> In summary, there is no safe window in which to revascularise a patient with a traumatised and ischaemic limb. These patients need to be prioritised within the hospital system. A management strategy with pre-operative CTA to delineate the extremity vascular injury, while preparing an operating room, could be valuable in selected patients and may not cause a treatment delay in most hospital systems nowadays.<sup>96</sup>

To reduce the risk of limb loss or ischaemic complications, restoration of in line arterial flow is considered an immediate

priority, with the best outcomes observed in those patients with the shortest overall ischaemic times. Arterial flow should be restored, temporarily or definitively, prior to skeletal stabilisation, fasciotomy, and or other procedures. Compartment syndrome is principally a reperfusion injury and fasciotomy should not be the primary procedure for ischaemic extremity vascular injury. A more detailed discussion with recommendations regarding the use of shunts is available in Sections 2.11. and 2.12.

Recommendation 85			
Revascularisation as soon as possible, ideally within one hour of admission, is recommended in patients with clinical evidence of acute ischaemia due to extremity vascular trauma.			
Class	Level	References	ToE
I	C	Alarhayem <i>et al.</i> (2019), <sup>107</sup> Perkins <i>et al.</i> (2022), <sup>409</sup> Glass <i>et al.</i> (2009), <sup>411</sup> Perkins <i>et al.</i> (2015), <sup>408</sup> Ray <i>et al.</i> (2019), <sup>124</sup> Zaraca <i>et al.</i> (2011), <sup>412</sup> Hsieh <i>et al.</i> (2022), <sup>413</sup> Chipman <i>et al.</i> (2023), <sup>410</sup> Lewis Jr <i>et al.</i> (2022), <sup>414</sup> Magnotti <i>et al.</i> (2020) <sup>415</sup>	

Recommendation 86			
The use of a temporary vascular shunt to rapidly restore blood flow in the extremity is recommended when timely primary definitive vascular repair is not feasible due to patient physiology or skeletal instability.			
Class	Level	References	ToE
I	C	Tung <i>et al.</i> (2021), <sup>111</sup> Borut <i>et al.</i> (2010), <sup>112</sup> Subramanian <i>et al.</i> (2008), <sup>113</sup> Polcz <i>et al.</i> (2021), <sup>117</sup> Laverty <i>et al.</i> (2022), <sup>118</sup> Feliciano <i>et al.</i> (2013) <sup>109</sup>	

**6.3.2. Penetrating extremity vascular trauma.** Whilst blunt trauma may result in more Grade 1 and Grade X injuries, penetrating trauma is more likely to cause exsanguinating extremity or junctional haemorrhage. Immediate management focuses on controlling haemorrhage, which may require direct pressure, tourniquets, or haemostatic agents. Tourniquets should be applied proximal to the wound and tightened until the bleeding stops. In junctional regions, tourniquets are unlikely to suffice, and rapid surgical or endovascular haemostasis is required. The basic principles of vascular haemorrhage control include proximal and distal control. Proximal control is usually achieved outside the zone of injury, and in junctional injuries may require entering different anatomical regions. The division of ligaments and or muscles (such as inguinal and shoulder girdle musculature) may be required to identify and control haemorrhage. As with blunt injuries, once the bleeding is controlled, the next priority is revascularisation

with shunting, primary repair, end to end anastomosis, or interposition grafts depending on the individual circumstances. Early surgical intervention is crucial for minimising ischaemic damage and improving long term outcomes.

### 6.3.3. Primary amputation

**6.3.3.1. Decision support tools.** The decision to proceed to revascularisation or amputation in complex extremity vascular trauma can be extremely difficult. The morphology of injury is not the only consideration when deciding to pursue limb revascularisation. Patient and limb factors, mechanism of injury, and even local environmental factors should all be evaluated to determine treatment. Several objective scoring systems have been developed to aid the clinician in complex decision making. The Mangled Extremity Severity Score (MESS) and Mangled Extremity Syndrome Index (MESI) are two of the more recognised but were formulated using retrospective data.<sup>416,417</sup>

**Upper limb.** A large systematic review of 6 113 upper limb trauma cases showed that the MESS alone does not accurately predict the need for amputation.<sup>418</sup> This finding has been supported by another systematic review of upper limb scoring systems.<sup>419</sup> The MESI may be more precise but was based on a single retrospective study. Other small case series have not shown high levels of evidence to support using scoring systems alone to guide management.<sup>420–424</sup>

**Lower limb.** A systematic review of 17 studies of lower extremity injury revealed that MESS was the most frequently used scoring system.<sup>425</sup> Overall, scoring systems were not useful in predicting functional limb salvage, or useful alone in predicting whether to amputate or reconstruct. Another small retrospective study supports the finding that MESS does not predict delayed amputation in patients with isolated popliteal arterial injuries.<sup>426</sup>

**Secondary amputation.** Perkins *et al.* performed a meta-analysis of 3 187 lower extremity vascular reconstructions. Factors associated with a substantial increase in amputation included soft tissue injury, presence of compartment syndrome, levels of arterial injury, duration of injury, and associated fractures.<sup>427</sup>

In summary, no contemporary scoring system on its own should be used to decide whether to salvage or amputate an injured extremity. A multidisciplinary, senior team based decision, taking into account limb injury extent, degree of ischaemia, physiology, and holistic patient factors, should be used to manage complex extremity vascular trauma.

Recommendation 87			
The use of scoring systems when deciding upon limb salvage or amputation for patients with extremity trauma is not recommended.			
Class	Level	References	ToE
IIIb	B	Schirò <i>et al.</i> (2015), <sup>425</sup> Loja <i>et al.</i> (2018), <sup>428</sup> Elshawary (2005), <sup>422</sup> Nayar <i>et al.</i> (2022), <sup>418</sup> Prichayudh <i>et al.</i> (2009), <sup>423</sup> Yoneda <i>et al.</i> (2024), <sup>419</sup> Gratl <i>et al.</i> (2023) <sup>426</sup>	

Recommendation 88			
Multidisciplinary decision making regarding revascularisation vs. primary amputation is recommended in patients with complex extremity trauma.			
Class	Level	References	ToE
I	B	Schirò <i>et al.</i> (2015), <sup>425</sup> Loja <i>et al.</i> (2018), <sup>428</sup> Elshawary (2005), <sup>422</sup> Nayar <i>et al.</i> (2022), <sup>418</sup> Prichayudh <i>et al.</i> (2009), <sup>423</sup> Yoneda <i>et al.</i> (2024), <sup>419</sup> Gratl <i>et al.</i> (2023) <sup>426</sup>	

**6.3.4. Non-occlusive extremity vascular injuries (ESVS Grade 1 and 2).** Non-occlusive extremity vascular injuries pose a therapeutic dilemma to the vascular surgeon. The natural history of non-flow limiting dissection, intimal injury, pseudoaneurysm, or AVF is not well understood.

There is a paucity of evidence on how to manage these injuries in the literature. Studies are generally of very low quality, so firm recommendations cannot be made. All are case studies or small retrospective case series. Dennis *et al.* attempted to follow up 44 non-occlusive extremity arterial injuries in 43 patients who had been treated non-operatively, consisting of intimal flaps, stenosis, pseudoaneurysms, and one fistula.<sup>429</sup> Four patients had clinical signs within a month requiring surgery. Of the remaining patients, 23 were contactable and 17 underwent examination and DUS. All were asymptomatic and only one had residual stenosis on ultrasound. Pan *et al.* reviewed 20 patients with lower limb traumatic pseudoaneurysms who were not treated non-operatively; ten patients received a stent graft, two were coil embolised, and eight had surgical repair (direct repair or venous repair).<sup>430</sup> All patients had a successful outcome. Frykberg *et al.* followed up 47 patients with 50 non-occlusive injuries; 22 had intimal flaps, 21 segmental narrowing, six pseudoaneurysms, and one AVF.<sup>431</sup> Forty six patients were followed up for a mean of 3.1 months; 89% required no treatment; five patients' clinical signs worsened and required immediate intervention.

Recommendation 89			
Non-operative management with clinical and imaging follow up may be considered for patients with extremity non-occlusive vascular injuries (ESVS Grade 1 or 2).			
Class	Level	References	ToE
IiB	C	Dennis <i>et al.</i> (1998), <sup>429</sup> Pan <i>et al.</i> (2014), <sup>430</sup> Frykberg <i>et al.</i> (1991) <sup>431</sup>	

**6.3.5. Open or endovascular repair (ESVS Grade 2, 3, and X).** Open arterial repair remains the most performed operative technique in patients with vascular trauma to the extremities. There are no comparative studies between the different types of open repair: primary repair,

patch repair, interposition, or bypass graft. The type of open surgical repair of vascular extremity trauma should be based upon the extent of the vascular injury (ESVS Grade 2, 3, or X), anatomy, physiology, and pre-existing patient factors. Endovascular repair is being deployed increasingly, but remains limited to <20% of reported cases.<sup>432,433</sup> In a comparative study using propensity scored matching in 786 patients with peripheral arterial traumatic injuries using the National Readmission Database, endovascular repair had a higher risk of re-admission and a higher 30 day open re-operation rate (6% vs. 2%;  $p < .01$ ), with no difference in mortality or amputation rates.<sup>432</sup> Other studies also found a significant risk of patency loss or re-interventions after endovascular repair.<sup>53,434,435</sup> In a retrospective analysis of the National Trauma Data Bank on endovascular vs. open treatment of isolated superficial femoral and popliteal artery injuries ( $n = 2873$ ) amputation free survival was not different, but after multivariable logistic regression analysis the in hospital mortality rate was higher for patients who received endovascular repair.<sup>436</sup> Endovascular embolisation for bleeding from tributary arteries is the most common and successful use of endovascular approaches to extremity injury.<sup>437-439</sup> Stent graft treatment of larger femoropopliteal pseudoaneurysms (ESVS Grade 2 injuries) has also been described.<sup>440</sup>

Recommendation 90			
Endovascular stent or stent graft repair may be considered as an alternative to open repair in selected patients with extremity vascular trauma requiring operative treatment (ESVS Grade 2, 3, or X).			
Class	Level	References	ToE
IiB	C	Asmar <i>et al.</i> (2021), <sup>432</sup> Butler <i>et al.</i> (2019), <sup>434</sup> Worni <i>et al.</i> (2013), <sup>441</sup> Magee <i>et al.</i> (2023), <sup>433</sup> Potter <i>et al.</i> (2021) <sup>436</sup>	

Recommendation 91			
Endovascular embolisation is recommended for active bleeding from side branches of major arteries in patients with extremity injuries.			
Class	Level	References	ToE
I	C	Maleux <i>et al.</i> (2012), <sup>438</sup> D'Alessio <i>et al.</i> (2020), <sup>437</sup> Cheraghali <i>et al.</i> (2021) <sup>439</sup>	

**6.3.6. Arterial injuries below the knee and elbow.** The collateral supply below the elbow and knee with the respective palmar and pedal arches reduces the need for repair of all injured vessels. Ligation of either the radial or ulnar artery in patients with an intact palmar arch is an acceptable treatment method.<sup>442</sup> In multiple tibial

vessel injury, there is limited evidence to guide the precise number of vessels that should be repaired although standard teaching has been that a single intact or repaired artery with a runoff distal to the ankle joint is usually sufficient for limb salvage.<sup>443</sup> Multiple tibial vessel injury is associated with higher rates of limb loss.<sup>443–447</sup> Rather than the overall number of tibial vessels injured determining outcomes, one study identified that the specific artery injured was associated with limb salvage. In a single centre study of 122 patients with single tibial vessel injury after blunt trauma, an injured anterior tibial artery was associated with a significantly higher amputation rate (6 of 17 patients, 35.3%) compared with those patients with either posterior tibial or peroneal injuries (3 of 34 patients, 8.8%;  $p = .045$ ).<sup>446</sup> The adjusted OR of requiring an amputation after blunt injury to the anterior tibial artery alone, compared with a posterior tibial or peroneal injury, was 22.4 ( $p = .02$ ).

Recommendation 92			
If repair is not easily achievable, ligation is recommended in isolated radial or ulnar arterial injury without evidence of distal ischaemia.			
Class	Level	References	ToE
I	C	Schippers <i>et al.</i> (2018) <sup>442</sup>	

Recommendation 93			
Ligation or embolisation of an isolated infragenicular arterial injury without evidence of distal ischaemia may be considered in patients with one of the anterior or posterior tibial arteries intact and patent.			
Class	Level	References	ToE
IIB	C	Lee <i>et al.</i> (2024), <sup>443</sup> Dua <i>et al.</i> (2015), <sup>444</sup> Croman <i>et al.</i> (2023) <sup>445</sup>	

**6.3.7. Intra-operative heparinisation.** Retrospective studies show conflicting results for systemic intra-operative heparinisation.<sup>448–450</sup> Analysis is hampered by retrospective study designs often with selection bias. Patients receiving systemic intra-operative heparinisation were often less severely injured than those who did not.<sup>448</sup> In a multicentre retrospective study ( $n = 323$  patients), patency of arterial repair was higher after systemic intra-operative heparinisation without increased bleeding, while data from the prospective PROOVIT study ( $n = 193$  patients) found increased blood product use after systemic heparinisation without a benefit in thrombosis or limb loss.<sup>449,450</sup> The decision for systemic intra-operative heparinisation or not may be based upon the extent of the repair, duration of interrupted blood flow, concomitant injuries, as well as overall risk of bleeding and degree of trauma induced coagulopathy.

Recommendation 94			
Intra-operative systemic heparinisation in patients with extremity trauma may be considered on an individual basis, including the extent of repair, duration of interrupted blood flow, concomitant injuries and overall risk of bleeding, and degree of trauma induced coagulopathy.			
Class	Level	References	ToE
IIB	C	Guerrero <i>et al.</i> (2002), <sup>448</sup> Maher <i>et al.</i> (2017) <sup>449</sup>	

**6.3.8. Extremity venous injuries.** Extremity venous injuries in isolation or in combination with arterial injuries require an individualised approach to decision making regarding repair vs. ligation. Combined arterial and venous injuries are often markers for greater trauma severity and complexity of injury to the extremity with overall higher rates of amputation, fasciotomy, and limb complications. In blunt trauma, combined vascular injuries are often associated with multisystem injury and therefore competing treatment priorities, e.g., control of torso haemorrhage to preserve life over limb. Since the Vietnam conflict, there have been a number of studies from civilian and more recent military conflicts, with a meta-analysis finding the risk of secondary amputation was six times lower following venous repair than venous ligation with no increased risk of venous thromboembolism.<sup>408</sup> However, to date there is no evidence to definitively support one approach over another, and patient physiology, injury burden to the limb as well as other body regions, and complexity of the venous injury must all be considered in determining the surgical strategy.

Most recently, outcomes were compared in over 300 US combat casualties with extremity vascular trauma and any venous injury, between those undergoing venous repair and venous ligation and no difference was found in vascular or limb complications (71.1% vs. 63.9%;  $p = .21$ ) or amputation rate (25.9% vs. 18.8%;  $p = .16$ ).<sup>451</sup> Despite higher extremity injury severity and more frequent fasciotomies, the authors concluded that concomitant venous injury was not associated with poorer limb salvage or complications, and repair of femoropopliteal venous injuries did not appear to influence limb outcomes. In a civilian registry review of over 2000 trauma patients with major venous extremity injury, those in the ligation group had significantly higher rates of fasciotomy and secondary amputation and longer hospital length of stay than those in the repair group (44.6% vs. 33.5%, risk ratio 1.33; 6.1% vs. 3.4%, risk ratio 1.81; median [interquartile range] 11 [6–20] days vs. 9 [5–17] days, respectively), although there were no significant differences in any other complications or in hospital death.<sup>452</sup> However, from the same registry, a study of popliteal vascular injuries (908 combined arterial and venous and 303 isolated venous injuries) found, in multivariable logistic regression, that ligation was not independently associated with in hospital amputation free survival, amputation, or death in those with isolated venous injury.<sup>453</sup>

For simple venous injuries and or isolated venous injuries, repair is supported; but in the context of multiple vascular injuries, haemodynamic instability, and or other treatment priorities to save life, then the role of venous repair is diminished with temporary venous shunting and delayed repair, or ligation as preferred surgical options.

Recommendation 95			
Repair of localised femoral or popliteal venous injury should be considered over ligation in haemodynamically stable patients.			
Class	Level	References	ToE
Iia	B	O'Shea <i>et al.</i> (2022), <sup>451</sup> Byerly <i>et al.</i> (2020), <sup>453</sup> Matsumoto <i>et al.</i> (2019), <sup>452</sup> Manley <i>et al.</i> (2018), <sup>454</sup> Perkins <i>et al.</i> (2015) <sup>408</sup>	

**6.3.9. Compartment syndrome and fasciotomy.** Acute extremity compartment syndrome is a surgical emergency associated with significant morbidity if not managed expeditiously. Data from the US National Trauma Data Bank showed that patients sustaining lower extremity arterial trauma required a fasciotomy in up to 42% of cases.<sup>455</sup> More recent US national data (Trauma Quality Improvement Program database, 2017 – 2019) found the fasciotomy rate following lower extremity vascular injury to be 6.7%, a notable reduction from previous reports.<sup>456</sup> The most important tool in diagnostics is to maintain a high level of clinical suspicion. Patients with classical clinical signs of compartment syndrome do not need any further investigation and should undergo urgent fasciotomy. Ischaemia duration after arterial vascular trauma exceeding 2.5 hours presented as a strong predictor for fasciotomy.<sup>457</sup> Compartment pressure is seldom measured routinely but has been used in patients with impaired awareness or consciousness.<sup>458</sup> There is little consensus about the threshold value for its diagnosis and treatment.

Early fasciotomy (within eight hours after open vascular repair) in patients with extremity vascular injury was associated with a four fold lower risk of amputation (OR 0.26, 95% CI 0.14 – 0.50;  $p < .0001$ ) and 23% shorter hospital length of stay (means ratio 0.77, 95% CI 0.64 – 0.94;  $p = .01$ ).<sup>455</sup> Incisions in the skin and fascia need to be long enough to make tissues loose and allow for post-operative swelling. The easiest and most common way to decompress the compartments is through two incisions: anterolateral (to open the anterior and lateral compartments) and posteromedial (to open the superficial and deep posterior compartments).<sup>458,459</sup> Fasciotomy of the forearm is performed with decompression of the volar and lateral compartments and the dorsal compartment.

There are many studies in the literature suggesting that delayed fasciotomy for compartment syndrome leads to worse outcomes whether in trauma or acute limb

ischaemia,<sup>455,460–462</sup> with Gordon *et al.* advocating prophylactic fasciotomy in any limb at risk of compartment syndrome in an austere environment.<sup>462</sup> More recent research has cast doubt on the benefit of prophylactic fasciotomy, however. A porcine model of prophylactic fasciotomy vs. no fasciotomy showed no functional difference after reperfusion.<sup>463</sup> A retrospective review of 101 patients showed selective use of fasciotomy with lower limb extremity injury spared almost half of the patients the need for fasciotomy, with no increase in complications.<sup>464</sup> Results from the PROOVIT registry of 158 patients showed no difference in outcomes between therapeutic and prophylactic fasciotomy.<sup>465</sup> Keating *et al.*, studying 436 patients prospectively across 18 centres, found that index fasciotomy did not demonstrate an outcome benefit, suggesting that careful observation and fasciotomy when required may reduce unnecessary surgery and morbidity.<sup>466</sup>

Recommendation 96			
Emergency four compartment fasciotomy is recommended to treat traumatic post-ischaemic lower limb compartment syndrome.			
Class	Level	References	ToE
I	B	von Keudell <i>et al.</i> (2015), <sup>458</sup> Farber <i>et al.</i> (2012), <sup>455</sup> Bible <i>et al.</i> (2013), <sup>467</sup> Etemad-Rezaie <i>et al.</i> (2022) <sup>468</sup>	

#### 6.4. Post-operative surveillance in extremity vascular trauma

Follow up and modalities vary in the literature after extremity vascular trauma reconstructions. These include clinical examination, measurement of ABI, and imaging follow up with colour coded DUS, but also CTA, at various intervals after the procedure.<sup>469,470</sup> DUS, CTA, MRI, or angiography have been suggested in patients who demonstrate worsening clinical manifestations and evidence of stenosis.<sup>435,471,472</sup>

In the peripheral arterial disease population, a recent Cochrane analysis showed no clear difference between DUS and standard surveillance in preventing limb amputation, morbidity, and death after lower limb revascularisation.<sup>473</sup> A recommendation for routine DUS surveillance of infrainguinal vein grafts remains dependent on low quality evidence; small number of events and high risk of bias in the literature.<sup>474</sup> When considering the non-invasive nature, low cost, and opportunity for intervention, DUS surveillance may be used for follow up of lower extremity vein grafts in patients with peripheral arterial disease.

There are inadequate data demonstrating the clinical benefit of a DUS surveillance programme after extremity vascular trauma reconstructions, but it is reasonable to assume that subgroups of patients with bypass or interposition graft or stent graft might benefit from surveillance.

Recommendation 97			
Post-operative follow up with clinical examination and duplex ultrasound one month after repair, or earlier if abnormal findings or symptoms develop, may be considered for patients with extremity vascular injury and vascular reconstruction.			
Class	Level	References	ToE
Ib	C	Dorweiler <i>et al.</i> (2003), <sup>469</sup> Abu Dabrh <i>et al.</i> (2017), <sup>474</sup> Sarpe <i>et al.</i> (2023) <sup>473</sup>	

## 7. POST-OPERATIVE GENERAL CONSIDERATIONS AFTER VASCULAR TRAUMA

Post-operative care follows the general principles of trauma management, particularly for multiple trauma patients. Vascular trauma patients should be admitted to a unit where the patient can be evaluated regularly, especially for the first 24 – 48 hours. Communication between the operative and the intensive care unit team about operative findings and the post-operative plan is paramount to prevent any possible complications.

Vascular status post injury and repair need to be assessed by physical examination, including pulse examination and Doppler, while colour coded DUS and CTA can be used on a selective basis. Coagulation status and rhabdomyolysis are monitored with laboratory blood tests. Extremities are evaluated clinically for development of a compartment syndrome that may require urgent fasciotomy. Compression stockings and intermittent pneumatic compression devices to prevent deep venous thrombosis and leg swelling as well as early physiotherapy for functional impairment have been well demonstrated in the trauma setting.

### 7.1. Post-operative surveillance

Optimal follow up and surveillance after vascular injury remains controversial. There is no evidence to support routine surveillance in all patients, however it is reasonable to assume that subgroups of patients might benefit from surveillance. The modification of guidelines from atherosclerotic vascular disease intervention protocols would seem ideal, but even in that setting controversy regarding optimal surveillance exists, and most patients with vascular trauma do not have a cardiovascular disease burden.<sup>54</sup> For specific surveillance recommendations, please see each chapter in these vascular trauma guidelines.

Following up with trauma patients presents several challenges that may impact recovery and long term outcome. Non-compliance with post-operative surveillance remains an issue after open or endovascular repair. Other challenges may include involvement of multiple healthcare providers and specialists, rehabilitation adherence, socio-economic barriers, psychological and emotional reactions, as well as cultural and language differences. Addressing these challenges requires a multidisciplinary approach and a commitment to patient centred health care.

By anticipating these potential barriers and proactively working to overcome them, healthcare providers can improve follow up compliance and patient outcomes.

### 7.2. Antibiotic prophylaxis after vascular trauma

Apart from general trauma recommendations for the use of peri-operative systemic antibiotics with preferred additional Gram negative coverage, there exists no evidence for or against the use of post-operative antibiotic prophylaxis after vascular trauma. Antibiotic prophylaxis will also vary across hospitals and countries. Therefore, considering the trauma setting diversity, injury types, and treatment methods, individualisation of post-operative antibiotic therapy seems reasonable. Type of antibiotics is also influenced if open fracture is present and the environment where the trauma took place. A prospective single centre study recommended the use of prophylactic antibiotics for the first 24 hours after stent graft treatment of penetrating carotid artery injuries, and an extremity vascular trauma study suggested continuing the use of pre-operative prophylactic antibiotics for 24 hours post-operatively.<sup>167,475</sup>

### 7.3. Post-operative antithrombotic therapy

The literature on antithrombotic therapy after vascular repair in patients with peripheral atherosclerotic disease cannot be generalised to most patients with arterial or venous repair for extremity vascular trauma.<sup>476</sup> There is limited literature on post-operative antithrombotic medication.<sup>477</sup> According to a meta-analysis by Khan *et al.*, anticoagulation may have some benefit in vascular trauma surgery of the peripheral extremity to reduce intra- and post-operative complications.<sup>477</sup> They found no increase in negative outcomes with anticoagulation use.<sup>477</sup> In contrast, a recent report using the American College of Surgeons Trauma Quality Improvement Program found that post-operative administration of unfractionated heparin was associated with increased bleeding complications in 4379 patients with peripheral arterial injuries.<sup>478</sup> In a prospective observational multicentre study, the influence of no antithrombotic vs. different regimens of antithrombotic therapy was investigated in 373 patients with arterial injuries repaired with a vein graft. No difference was seen for in hospital operative re-intervention or thrombosis, but more long term use of antithrombotics was beyond the scope of the study.<sup>479</sup> Also, in a small retrospective comparative matched analysis, no difference regarding bleeding or thrombosis was seen with the use of aspirin or intravenous heparin at therapeutic dose vs. no antithrombotics.<sup>480</sup> While there is a concern for post-operative haemorrhage, there is also a competing risk of thrombosis of the reconstruction, and practices vary widely.<sup>479</sup> An individualised post-operative antithrombotic strategy has been advised. Patient risk factors, including bleeding and thrombotic risk as well as complexity of vascular repair, need to be assessed when deciding an antithrombotic regimen.



Recommendation 98			
Post-operative single antiplatelet therapy may be considered for patients with vascular trauma who have undergone open or endovascular repair.			
Class	Level	References	ToE
I <b>ib</b>	C	Khan <i>et al.</i> (2020), <sup>477</sup> Stonko <i>et al.</i> (2023) <sup>479</sup>	

## 8. PAEDIATRIC VASCULAR TRAUMA

### 8.1. General considerations

Traumatic vascular injuries in children are relatively rare.<sup>13,481</sup> There is a general lack of clinical evidence, which makes it difficult to make firm management recommendations. The text will try to provide the best available data to guide management. Paediatric vascular trauma poses challenges because of smaller arteries that are prone to vasospasm, small intravascular volume, the need for future vessel growth (longitudinal and circumferential), and consideration of long term durability.<sup>6</sup> Children also possess an effective compensatory ability that sometimes justifies a non-operative management approach.

For diagnostic investigations in children, CTA has been the most reported imaging modality performed, with high sensitivity and specificity both for blunt and penetrating vascular trauma.<sup>6,91,95</sup>

Recommendation 99			
Computed tomography angiography is recommended as the first line investigation to identify or rule out vascular injury in haemodynamically stable paediatric trauma patients.			
Class	Level	References	ToE
I	C	Patterson <i>et al.</i> (2012), <sup>95</sup> Moody <i>et al.</i> (2024) <sup>6</sup>	

Repair of traumatic vessel injury in children, particularly infants, is challenging regarding the choice of conduit. There is no high quality evidence to recommend autologous or synthetic graft material, but vein may be more suitable for small calibre vessels in children. Interrupted sutures to avoid post-operative stenosis due to the purse string effect and to prevent narrowing of the anastomosis associated with growth have been described.<sup>482</sup> The risk of vein graft dilatation is expected over time. Again, if rapid restoration of flow is needed and there is a vessel diameter mismatch, a synthetic interposition graft may be the best solution, with some advocating sewing the graft with some slack to accommodate growth. Also, the experience with stent graft repair, e.g., in the aorta, and sizing is limited.

### 8.2. Neck vessel injuries

The incidence of BCVI may be as high in children as in adults.<sup>192,483–485</sup> There are few data on the management of vascular neck injuries in children as well as the interpretation of CTA imaging findings. Small studies suggest that a

selective individualised management strategy is safe.<sup>486–488</sup> Minor lesions (ESVS Grade 1 and 2) can be treated with antiplatelet or anticoagulant drugs.<sup>486–488</sup> There is no strong evidence to recommend a specific antithrombotic agent. The most recent meta-analysis was in favour of using a single antiplatelet agent but excluded all studies in paediatric patients (<18 years of age).<sup>204</sup> In a small retrospective study with patients aged <10 years diagnosed with BCVI, there were no observed differences in the rate of haemorrhagic complications between anticoagulation and antiplatelet therapy, but a non-significant better rate of healing on follow up imaging in children who underwent antiplatelet therapy.<sup>489</sup> Enlarging pseudoaneurysm or active bleeding (ESVS Grade 2 or 3) can be approached by embolisation or open repair.<sup>488,490</sup> Follow up must be long term to ensure effective remodelling of the artery.<sup>491</sup> Paediatric oropharyngeal injuries are a rare cause of ICA injury with bleeding, dissection, thrombosis, or embolisation, and have only been described in a limited number of case series.

Recommendation 100		
Early antithrombotic therapy is recommended for children with blunt, low grade carotid artery injury (ESVS Grade 1 or 2).		
Class	Level	References
I	C	Consensus

### 8.3. Thoracic aortic injury

BTAI in children is rare. Among 26 940 children with a blunt mechanism of injury, 34 children (0.1%) sustained a thoracic aortic injury, 14 (41%) of whom died.<sup>492</sup> Older children involved in a motor vehicle collision with severe head, torso, and lower extremity injuries are a group at high risk of BTAI. As in adults, physiology and concomitant injuries on admission can jeopardise open repair, while endovascular repair is complicated by the small diameter of the aorta and or access vessels and hostile configuration of the aortic arch. Long term results are not available. Regardless of these disadvantages, TEVAR is accepted as a lifesaving or bridging procedure (ESVS Grade 2 and 3). Published experience of TEVAR for BTAI in children is limited. Hosn *et al.* identified fewer than 20 patients younger than 18 years old treated by endovascular repair.<sup>493</sup> Rauli *et al.* analysed the American National Trauma Data Bank and found that adult patients had significantly higher rates of TEVAR than children (3% children, 25.2% adolescent, and 29.2% adult patients) and that children were most likely to receive non-operative management (94% children, 67.9% adolescent, and 64.8% adult patients).<sup>494</sup> An initial non-operative approach to small pseudoaneurysms (ESVS Grade 2) seems reasonable in children. Midterm complications faced in children and young individuals are related to oversizing and bird beak causing collapse, migration, stenosis, or occlusion of the stent graft.<sup>495–497</sup> In an acute setting, stenosis with or without complete thrombosis and collapse are the most devastating complications presenting with sudden hypertension, claudication, spinal cord ischaemia, acute renal

impairment, and visceral malperfusion.<sup>379,498</sup> In the long term, chronic effects of the stent graft on the heart and vasculature could be an issue (myocardial injury, aortic remodelling with elongation of the arch and aortic stiffness) and will need further analysis. Prevention or control of all these complications is needed by continuous monitoring and timely re-intervention or conversion to open repair when necessary. Patients and parents should be informed of the need for long term follow up.

Recommendation 101			
Endovascular stent graft repair should be considered as the first line operative treatment for children with blunt thoracic aortic injury (ESVS Grade 2 or 3) and appropriate anatomy.			
Class	Level	References	ToE
Iia	C	Hosn <i>et al.</i> (2017), <sup>493</sup> Raulli <i>et al.</i> (2023) <sup>494</sup>	

#### 8.4. Abdominal vascular injuries

From a National Trauma Data Bank study of vascular injuries in the paediatric population ( $n = 1\,138$ ) by Barmparas *et al.*, abdominal vascular injuries (AVIs), the second most commonly injured region, were reported in 24.2%.<sup>13</sup> CTA is the gold standard in diagnosing AVI with 100% sensitivity, 93% specificity, 85% positive predictive value, and 100% negative predictive value.<sup>91,340,499</sup> The majority of abdominal trauma in children is managed non-operatively, but haemodynamic instability despite maximum resuscitative efforts mandates emergency laparotomy.<sup>500</sup> Management strategies for paediatric AVI parallels the adult trauma population. Open and endovascular treatment modalities are challenged by the size of the vessel encountered, and appropriate accommodations in graft and device selection are required. Caution should be taken to prevent vessel narrowing due to growth. This may include bevelled anastomosis with interrupted sutures as well as using a slightly longer Dacron graft.

Recommendation 102			
Immediate surgical exploration and bleeding control are recommended for children in shock with ongoing haemorrhage and suspicion of major abdominal vascular injury.			
Class	Level	References	ToE
I	C		Consensus

#### 8.5. Extremity vascular trauma

The extremity is the dominating anatomic location in paediatric vascular trauma. A recent systematic review found that the upper extremity is more prone to vascular trauma in children than the lower extremity.<sup>6</sup> In young children, blunt extremity injuries are most common (road traffic collision, fall, sport related), with penetrating extremity injury (glass, gunshot, or stab wound) becoming more prevalent in older children. Most often primary repair can be performed. Unfortunately, there are no comparative studies on the type of

repair or repair technique. Interrupted sutures are mentioned, preventing narrowing of the anastomosis that might occur with the growth of the patient.<sup>482</sup> Long term complications are rare after repair for extremity vascular trauma in children, and even in cases where bypass grafts occlude no clinical consequences occurred according to a recent systematic review.<sup>6</sup> Also, no incidents of length discrepancy were found.

Recommendation 103			
Clinical vascular examination in line with adult guidance is recommended in all children with upper or lower extremity trauma to identify potential haemorrhagic or ischaemic vascular injuries.			
Class	Level	References	ToE
I	C		Consensus

Supracondylar humeral fracture in children is the most common fracture in the elbow, with injury to the brachial artery occurring in approximately 8 – 12%.<sup>501</sup> Closed reduction and fixation of the fracture should be the priority in all pulseless supracondylar humeral fractures, and if there remains a poorly perfused pale hand immediate surgical exploration of the artery is indicated. There is continued support in the literature that a child with a pink pulseless hand post-fracture reduction can be managed expectantly unless additional signs of vascular compromise develop, in which case exploration should be undertaken.<sup>501-503</sup>

Recommendation 104			
Non-operative management should be considered in a child with a pink and warm, but pulseless, hand post-supracondylar humeral fracture reduction with close observation for the development of acute ischaemia.			
Class	Level	References	ToE
Iia	C	Delniotis <i>et al.</i> (2019), <sup>501</sup> Goh <i>et al.</i> (2024), <sup>502</sup> Griffin <i>et al.</i> (2008) <sup>503</sup>	

Several specialists including vascular surgeons, alongside paediatric surgeons, general, plastic and orthopaedic surgeons, and interventional radiologists, play an important role in the multidisciplinary management of children with extremity vascular injuries.

#### 8.6. Post-operative considerations

A standard protocol for antithrombotic therapy does not exist for paediatric patients after vascular trauma. Antiplatelet therapy using aspirin or clopidogrel and weight based dosing for the administration of LMWH have been suggested.<sup>489</sup> Follow up recommendations in some studies consisted of clinical examination and colour coded DUS after vascular repair and for graft surveillance in children treated for arterial ischaemia following trauma.<sup>482,504</sup> Surveillance CTA should be avoided in children if not absolutely necessary. There is little evidence regarding the frequency of follow up.

Recommendation 105		
Post-operative follow up with clinical examination and duplex ultrasound one month after repair, or earlier if abnormal findings or symptoms develop, may be considered for children with extremity vascular injury reconstructed with bypass or interposition graft.		
Class	Level	References
IIb	C	Consensus

## 9. GAPS IN EVIDENCE/RECOMMENDATIONS FOR FUTURE RESEARCH

In general, trauma research needs large scale prospective studies and RCTs to evaluate management strategies and to deliver new therapeutic interventions. Due to the paucity of literature on vascular trauma, recommendation on the optimal management strategy in some areas is left to the discretion of the operating surgeon to decide based upon the extent of the vascular injury, physiological status of the patient, concurrent injuries, contamination, and external circumstances such as mass casualty incidents. Historically, a relatively small fraction of health research expenditure has been spent on trauma research in relation to the significant burden of disease on

society. There are now more networks and multicentre institutions prioritising trauma research and conducting clinical trials. Artificial intelligence may have an increased role in the future. There are, for example, two reports showing that machine learning may be able to accurately predict the outcome of limb salvage.<sup>427,505</sup>

There are several unanswered questions in vascular trauma identified by the GWC as being research priorities for the future. These involve situations where there were either no data or conflicting evidence that did not allow recommendations to be made.

All these issues contribute to the broad spectrum of gaps in vascular trauma evidence, of which the most relevant are listed in Table 12.

## 10. PATIENTS' PERSPECTIVES

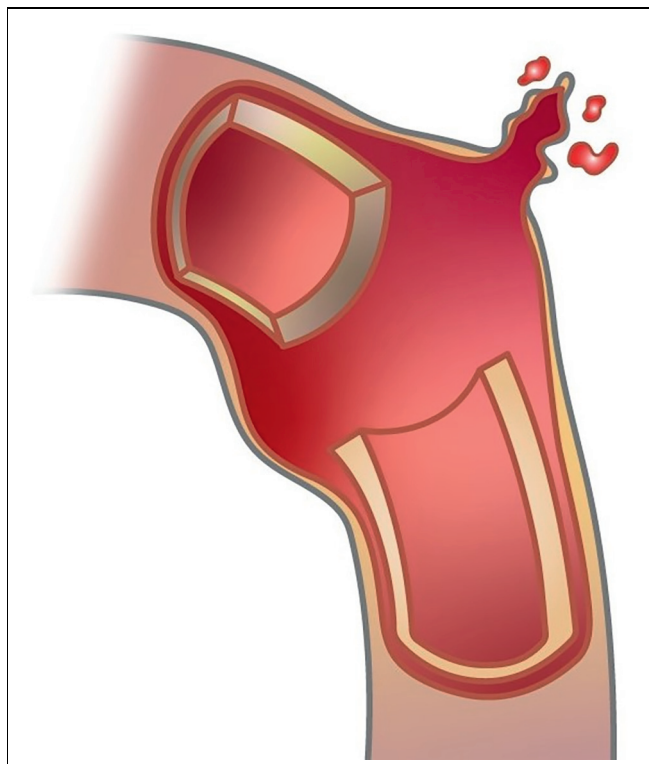
### 10.1. Introduction

Vascular trauma, or an injury to a blood vessel, can happen to anyone. Arteries and veins are the blood vessels that transport blood around the body. Arteries carry blood away from the heart, while veins return it. Injury to the blood vessels by a tear, crush, or puncture can lead to bleeding

**Table 12. Main evidence gaps in the management of patients with vascular trauma.**

General
European vascular trauma epidemiology data are scarce
The optimal duration of temporary intravascular shunts is not yet defined
Selection of patients who may benefit from resuscitative endovascular balloon occlusion needs definition
There are issues of long term patency and durability after endovascular stents and stent grafts
Hybrid operating room and improved outcome of vascular trauma
The role of graft material such as bovine or human acellular matrix grafts for arterial reconstruction
Assessment of timing of anticoagulant delivery and doses after vascular trauma
Neck
Antithrombotic regimens and duration after blunt or penetrating carotid artery injury
Comparison between antithrombotic treatments for BCVI; aspirin vs. low molecular weight heparin
Follow up imaging intervals after BCVI
Thoracic
The role of non-operative management of ESVS Grade I and small grade II BTAI
The role and timing of TEVAR for BTAI in patients with associated traumatic brain injury
There is a need to define specific risk factors for early aortic rupture in patients with BTAI, and the ideal timing for operative intervention
The long term durability of endovascular devices used for BTAI treatment remains to be determined
Graft sizing and graft use in paediatric BTAI patients, or patients with small aortic diameters, are inadequately studied
Imaging surveillance protocols need to be defined in patients treated with TEVAR for BTAI
Abdominal
Optimal management strategy for mesenteric vessel injury
Renal ischaemia time after trauma and kidney salvage
Optimal management strategy for renal vessel injuries
A contemporary prospective multicentre study is needed to compare ligation vs. repair of IVC injuries
Extremity
Decision to proceed to revascularisation or amputation in complex extremity vascular trauma
Comparative studies of open or endovascular repair for extremity arterial trauma, and data on long term follow up
Optimal management of occult vascular injuries
Operative strategy for extremity venous injuries
Post-operative surveillance and antithrombotic regimen after arterial reconstruction
Miscellaneous
Definition of adequate clinical trial endpoints in vascular trauma

BCVI = blunt cervical vascular injury; ESVS = European Society for Vascular Surgery; BTAI = blunt thoracic aortic injury; TEVAR = thoracic endovascular aortic repair; IVC = inferior vena cava.



**Figure 5.** Injury to blood vessel with bleeding.

(Fig. 5) but also formation of blood clots that can cause blockage of blood flow. The most common injuries are to arteries and veins of the legs and arms.

Vascular trauma in civilian practice most commonly arises from fall, traffic accidents, and knife and gun violence. Vascular trauma is managed by multidisciplinary teams, including vascular and trauma or general surgeons as well as anaesthetists, orthopaedic surgeons, and interventional radiologists. A referral to a trauma centre or hospital with this multispecialty expertise is recommended to treat complex vascular injuries.

### 10.2. Symptoms and diagnosis of vascular trauma

Blood vessel injuries can cause a variety of symptoms depending on the body location. Symptoms include severe bleeding or swelling called haematoma, but also signs of decreased circulation in the limbs including pain, pallor, and loss of pulses. A vascular injury can be diagnosed by physical examination alone, but most commonly in the case of multiple injuries diagnostic imaging is needed with CT scanning in hospital.

### 10.3. How to stop severe bleeding?

Severe bleeding is the major cause of preventable death from trauma. A person with uncontrolled bleeding can die within minutes, so it is important to quickly stop blood loss. For severe bleeding, take the following first aid steps:

- **Call** the local medical emergency services.
- **Find the bleeding injury** by open or removing clothing if needed.

- **Apply pressure to stop the bleeding** by pushing, preferably using a clean cloth, directly on the wound with both hands (Fig. 6).
- While waiting for emergency help to arrive, try to keep the injured person warm and from moving.

### 10.4. Management

Up to half of all trauma deaths within the first 24 hours after injury are attributable to major bleeding. The priority in vascular trauma is therefore to control bleeding, and the second priority is to restore circulation to the brain or to organs, e.g., in the abdomen or in the leg to prevent amputation.

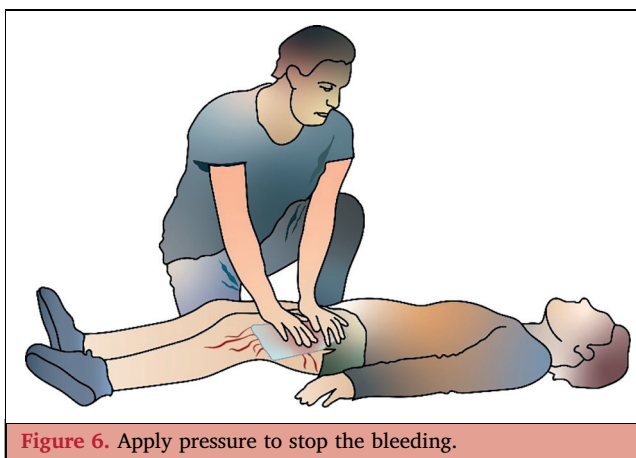
Minor vascular injuries can be managed with non-operative treatment, including blood thinner medication. Sometimes an injured vessel can just simply be tied off during operation. However, major vascular injuries usually require surgical repair with sutures or with a graft (vein or prosthetic artificial graft). Minimally invasive techniques (endovascular techniques) can be an option for some vascular injuries to plug the vessel or to use a stent graft (a metal tube covered with polyester) to cover the injury and keep the vessel open.

### 10.5. Follow up

Each person with a vascular injury and path to recovery is different. When it is time to leave the hospital, there should be an after hospital plan of care, including medications and follow up appointments. Some people may be discharged directly home. However, many people need specialised care after they leave the hospital, which may include physical therapy and rehabilitation. There may also be other associated injuries that require further care. Going through a traumatic injury may cause a range of strong emotions, sometimes requiring professional help. A delayed emotional reaction to trauma may occur as well. It is important to have regular follow up visits with the physician and the hospital services in charge. Sometimes imaging will be carried out, such as ultrasound or CT, to determine the performance of the vascular repair.

### 10.6. Outcome

Vascular trauma is a serious condition with risk of life and limb loss. Modern trauma care in specialised hospitals with multidisciplinary trauma teams improves patient outcomes.



**Figure 6.** Apply pressure to stop the bleeding.

## ACKNOWLEDGEMENTS

Vascular surgeons in training that contributed to these guidelines: Dr Manik Chana, UK; Dr William Cullen, UK; Dr Davina Daudu, Australia; Dr Lucie Derycke, France; Dr Megan Fox, Ireland; Dr Aurélien Hostalrich, France; Dr Thomas Mesnard, France; Dr Nick Moody, UK; Dr Alexandre Pouhin, France; Dr Prashanth Ramaraj, UK; Dr Hannah O'Reilly, UK; Dr Alessandro Serafini, Italy; Dr Matt Spreadbury, Norway; Dr David Strachan, UK; Dr Amy Walter, UK; and Dr Jade Whing, UK. Illustrations: Mats Ceder, Sweden.

## APPENDIX A. SUPPLEMENTARY DATA

Supplementary data to this article can be found online at <https://doi.org/10.1016/j.ejvs.2024.12.018>.

## APPENDIX B. AUTHORS' AFFILIATIONS

### Writing Committee

Carl Magnus Wahlgren (Chair), Karolinska Institutet, Stockholm, and Department of Vascular Surgery, Karolinska University Hospital, Sweden; Karim Brohi (Co-Chair), Queen Mary University of London, London, UK; Jean-Baptiste Ricco (Co-Chair), University of Poitiers, Medical School, Poitiers, France; Christopher Aylwin, Centre for Trauma Sciences, Blizzard Institute, Queen Mary University of London, London, UK; Ross A. Davenport, Royal London Major Trauma Centre, Barts Health, London, UK and Centre for Trauma Sciences, Blizzard Institute Queen Mary University of London, London, UK; Lazar B. Davidovic, Faculty of Medicine, University of Belgrade Clinic for Vascular and Endovascular Surgery, University Clinical Centre of Serbia, Belgrade, Serbia; Joseph J. DuBose, University of Texas — Austin, Austin, TX, USA; Christine Gaarder, Department of Traumatology, Oslo University Hospital and Institute of Clinical Medicine, University of Oslo, Oslo, Norway; Catherine Heim, Anaesthetics Department, University Hospital, Lausanne, Switzerland; Vincent Jongkind, Amsterdam UMC, Amsterdam, the Netherlands; Joakim Jørgensen, Departments of Traumatology and Vascular Surgery, Oslo University Hospital, and Institute of Clinical Medicine, Faculty of Medicine, University of Oslo, Oslo, Norway; Stavros K. Kakkos, Department of Vascular Surgery, University of Patras, Patras, Greece; David T. McGreevy, Department of Cardiothoracic and Vascular Surgery, Örebro University Hospital, Örebro University, Örebro, Sweden; Maria Antonella Ruffino, Interventional Radiology, Imaging Institute of Southern Switzerland, EOC, Lugano, Switzerland; Melina Vega de Ceniga, Department of Angiology and Vascular Surgery, University Hospital of Galdakao-Usansolo, Galdakao, Spain, and University of the Basque Country (UPV/EHU), Leioa, Spain, and BioBizkaia Research Institute, Barakaldo, Spain; Pirkka Vikatmaa, Helsinki University Hospital, Abdominal Centre, Vascular Surgery, Helsinki, Finland.

### ESVS Guidelines Committee

George A. Antoniou, Manchester Vascular Centre, Manchester University NHS Foundation Trust, Manchester, UK,

and Division of Cardiovascular Sciences, School of Medical Sciences, Manchester Academic Health Science Centre, The University of Manchester, Manchester, UK; Jonathan R. Boyle, Cambridge University Hospitals NHS Trust and Department of Surgery, University of Cambridge, Cambridge, UK; Raphaël Coscas, Ambroise Paré University Hospital, AP-HP, Boulogne-Billancourt, France; Nuno V. Dias, Department of Clinical Sciences Malmö, Lund University and Vascular Centre Malmö, Skåne University Hospital, Malmö, Sweden; Barend M.E. Mees, Maastricht UMC+, Maastricht, the Netherlands; Santi Trimarchi, Department of Clinical and Community Sciences, University of Milan, Milan, Italy, and Cardiac Thoracic Vascular Department, Fondazione IRCCS Cà Granda Ospedale Maggiore Policlinico, Milan, Italy; Christopher P. Twine, North Bristol NHS Trust and University of Bristol, Bristol, UK; Isabelle Van Herzeele, Department of Thoracic and Vascular Surgery, Ghent University Hospital, Ghent, Belgium; Anders Wanhainen, Department of Surgical Sciences, Vascular Surgery, Uppsala University, Uppsala, Sweden, and Department of Diagnostics and Intervention, Surgery, Umeå University, Umeå, Sweden.

### Document Reviewers

Paul Blair, Royal Victoria Hospital, Belfast, Northern Ireland, UK; Ian D.S. Civil, Auckland City Hospital, Auckland, New Zealand and University of Auckland, Faculty of Medical and Health Sciences, Auckland, New Zealand; Michael Engelhardt, Department of Vascular and Endovascular Surgery, Military Hospital Ulm, Ulm, Germany, Erica L. Mitchell, University of Tennessee Health and Science University, Memphis, TN, USA; Gabriele Piffaretti, Vascular Surgery, Department of Medicine and Surgery, University of Insubria School of Medicine, Varese, Italy; Sabine Wipper, Department of Vascular Surgery, Medical University Innsbruck, Innsbruck, Austria.

## REFERENCES

- 1 GBD 2019 Diseases and Injuries Collaborators. Global burden of 369 diseases and injuries in 204 countries and territories, 1990–2019: a systematic analysis for the Global Burden of Disease Study 2019. *Lancet* 2020;**396**:1204–22.
- 2 Faulconer ER, Branco BC, Loja MN, Grayson K, Sampson J, Fabian TC, et al. Use of open and endovascular surgical techniques to manage vascular injuries in the trauma setting: a review of the American Association for the Surgery of Trauma PROspective Observational Vascular Injury Trial registry. *J Trauma Acute Care Surg* 2018;**84**:411–7.
- 3 Feliciano DV. For the patient—evolution in the management of vascular trauma. *J Trauma Acute Care Surg* 2017;**83**:1205–12.
- 4 Siracuse JJ, Cheng TW, Farber A, James T, Zuo Y, Kalish JA, et al. Vascular repair after firearm injury is associated with increased morbidity and mortality. *J Vasc Surg* 2019;**69**:1524–31.
- 5 Heldenberg E, Givon A, Simon D, Bass A, Almogy G, Peleg K. Terror attacks increase the risk of vascular injuries. *Front Public Health* 2014;**2**:47.
- 6 Moody N, Walter A, Daudu D, Wahlgren CM, Jongkind V. Editor's Choice – International perspective on extremity vascular trauma in children: a scoping review. *Eur J Vasc Endovasc Surg* 2024;**68**:257–64.

- 7 Twine CP, Wanhainen A. The new European Society for Vascular Surgery clinical practice guidelines recommendation grading system. *Eur J Vasc Endovasc Surg* 2024; doi: 10.1016/j.ejvs.2024.08.013 [epub ahead of print].
- 8 Brouwers MC, Kerkvliet K, Spithoff K, AGREE NextSteps Consortium. The AGREE reporting checklist: a tool to improve reporting of clinical practice guidelines. *BMJ* 2016;**352**:i1152.
- 9 Perkins ZB, De'Ath HD, Aylwin C, Brohi K, Walsh M, Tai NR. Epidemiology and outcome of vascular trauma at a British major trauma centre. *Eur J Vasc Endovasc Surg* 2012;**44**:203–9.
- 10 Branco BC, DuBose JJ, Zhan LX, Hughes JD, Goshima KR, Rhee P, et al. Trends and outcomes of endovascular therapy in the management of civilian vascular injuries. *J Vasc Surg* 2014;**60**:1297–307.
- 11 Fox CJ, Gillespie DL, O'Donnell SD, Rasmussen TE, Goff JM, Johnson CA, et al. Contemporary management of wartime vascular trauma. *J Vasc Surg* 2005;**41**:638–44.
- 12 Franz RW, Shah KJ, Halaharvi D, Franz ET, Hartman JF, Wright ML. A 5-year review of management of lower extremity arterial injuries at an urban level I trauma center. *J Vasc Surg* 2011;**53**:1604–10.
- 13 Barmparas G, Inaba K, Talving P, David JS, Lam L, Plurad D, et al. Pediatric vs adult vascular trauma: a National Trauma Databank review. *J Pediatr Surg* 2010;**45**:1404–12.
- 14 Konstantinidis A, Inaba K, Dubose J, Barmparas G, Lam L, Plurad D, et al. Vascular trauma in geriatric patients: a National Trauma Databank review. *J Trauma* 2011;**71**:909–16.
- 15 Barbati ME, Hildebrand F, Andruszkow H, Lefering R, Jacobs MJ, Jalaie H, et al. Prevalence and outcome of abdominal vascular injury in severe trauma patients based on a TraumaRegister DGU international registry analysis. *Sci Rep* 2021;**11**:20247.
- 16 Weber CD, Lefering R, Kobbe P, Horst K, Pishnamaz M, Sellei RM, et al. Blunt cerebrovascular artery injury and stroke in severely injured patients: an international multicenter analysis. *World J Surg* 2018;**42**:2043–53.
- 17 Johannesdottir BK, Geisner T, Gubberud ET, Gudbjartsson T. Civilian vascular trauma, treatment and outcome at a level I-trauma centre. *Scand J Trauma Resusc Emerg Med* 2022;**30**:74.
- 18 Bowley DMG, Degiannis E, Goosen J, Boffard KD. Penetrating vascular trauma in Johannesburg, South Africa. *Surg Clin North Am* 2002;**82**:221–35.
- 19 Nyberger K, Caragounis EC, Djerf P, Wahlgren CM. Management and outcomes of firearm-related vascular injuries. *Scand J Trauma Resusc Emerg Med* 2023;**31**:35.
- 20 White JM, Stannard A, Burkhardt GE, Eastridge BJ, Blackburne LH, Rasmussen TE. The epidemiology of vascular injury in the wars in Iraq and Afghanistan. *Ann Surg* 2011;**253**:1184–9.
- 21 Patel JA, White JM, White PW, Rich NM, Rasmussen TE. A contemporary, 7-year analysis of vascular injury from the war in Afghanistan. *J Vasc Surg* 2018;**68**:1872–9.
- 22 Sharrock AE, Tai N, Perkins Z, White JM, Remick KN, Rickard RF, et al. Management and outcome of 597 wartime penetrating lower extremity arterial injuries from an international military cohort. *J Vasc Surg* 2019;**70**:224–32.
- 23 Vuoncino M, Soo Hoo AJ, Patel JA, White PW, Rasmussen TE, White JM. Epidemiology of upper extremity vascular injury in contemporary combat. *Ann Vasc Surg* 2020;**62**:98–103.
- 24 Nyberger K, Strommer L, Wahlgren CM. A systematic review of hemorrhage and vascular injuries in civilian public mass shootings. *Scand J Trauma Resusc Emerg Med* 2023;**31**:30.
- 25 Heldenberg E, Givon A, Simon D, Bass A, Almogy G, Israeli Trauma Group, et al. Civilian casualties of terror-related explosions: the impact of vascular trauma on treatment and prognosis. *J Trauma Acute Care Surg* 2016;**81**:435–40.
- 26 Haas B, Stukel TA, Gomez D, Zagorski B, De Mestral C, Sharma SV, et al. The mortality benefit of direct trauma center transport in a regional trauma system: a population-based analysis. *J Trauma Acute Care Surg* 2012;**72**:1510–15.
- 27 Alharbi RJ, Lewis V, Shrestha S, Miller C. Effectiveness of trauma care systems at different stages of development in reducing mortality: a systematic review and meta-analysis protocol. *BMJ Open* 2021;**11**:e047439.
- 28 American College of Surgeons Committee on Trauma. *Resources for Optimal Care of the Injured Patient*. Chicago, IL: American College of Surgeons; 2022.
- 29 Metcalfe D, Bouamra O, Parsons NR, Aletrari MO, Lecky FE, Costa ML. Effect of regional trauma centralization on volume, injury severity and outcomes of injured patients admitted to trauma centres. *Br J Surg* 2014;**101**:959–64.
- 30 Galvagno SM Jr, Nahmias JT, Young DA. Advanced Trauma Life Support® update 2019: management and applications for adults and special populations. *Anesthesiol Clin* 2019;**37**:13–32.
- 31 Ferrada P, Ferrada R, Jacobs L, Duchesne J, Ghio M, Joseph B, et al. Prioritizing circulation to improve outcomes for patients with exsanguinating injury: a literature review and techniques to help clinicians achieve bleeding control. *J Am Coll Surg* 2024;**238**:129–36.
- 32 Rossaint R, Afshari A, Bouillon B, Cerny V, Cimpoesu D, Curry N, et al. The European guideline on management of major bleeding and coagulopathy following trauma: sixth edition. *Crit Care* 2023;**27**:80.
- 33 Kanani AN, Hartshorn S. NICE clinical guideline NG39: Major trauma: assessment and initial management. *Arch Dis Child Educ Pract Ed* 2017;**102**:20–3.
- 34 Chung CY, Scalea TM. Damage control surgery: old concepts and new indications. *Curr Opin Crit Care* 2023;**29**:666–73.
- 35 Latif RK, Clifford SP, Baker JA, Lenhardt R, Haq MZ, Huang J, et al. Traumatic hemorrhage and chain of survival. *Scand J Trauma Resusc Emerg Med* 2023;**31**:25.
- 36 Duchesne J, Slaughter K, Puente I, Berne JD, Yorkgitis B, Mull J, et al. Impact of time to surgery on mortality in hypotensive patients with noncompressible torso hemorrhage: an AAST multicenter, prospective study. *J Trauma Acute Care Surg* 2022;**92**:801–11.
- 37 DuBose JJ, Morrison JJ, Scalea TM, Rasmussen TE, Feliciano DV, Moore EE. Beyond the crossroads: who will be the caretakers of vascular injury management? *Ann Surg* 2020;**272**:236–7.
- 38 Burkhardt GE, Rasmussen TE, Propper BW, Lopez PL, Gifford SM, Clouse WD. A national survey of evolving management patterns for vascular injury. *J Surg Educ* 2009;**66**:239–47.
- 39 Harfouche MN, Kauvar DS, Feliciano DV, Dubose JJ. Managing vascular trauma: trauma surgeons versus vascular surgeons. *Am Surg* 2022;**88**:1420–6.
- 40 Brooks A, Butcher W, Walsh M, Lambert A, Browne J, Ryan J. The experience and training of British general surgeons in trauma surgery for the abdomen, thorax and major vessels. *Ann R Coll Surg Engl* 2002;**84**:409–13.
- 41 Strumwasser A, Grabo D, Inaba K, Matsushima K, Clark D, Benjamin E, et al. Is your graduating general surgery resident qualified to take trauma call? A 15-year appraisal of the changes in general surgery education for trauma. *J Trauma Acute Care Surg* 2017;**82**:470–80.
- 42 Yan H, Maximus S, Koopmann M, Keeley J, Smith B, Virgilio C, et al. Vascular trauma operative experience is inadequate in general surgery programs. *Ann Vasc Surg* 2016;**33**:94–7.
- 43 Smith S, Cattle P, Mador B, Paton-Gay JD, Bradley NL. Damage-control vascular surgery in Canada: supporting surgeons and teams. *Can J Surg* 2024;**67**:E247–9.
- 44 Parihar S, Benarroch-Gampel J, Teodorescu V, Ramos C, Minton K, Rajani RR. Vascular surgeons carry an increasing responsibility in the management of lower extremity vascular trauma. *Ann Vasc Surg* 2021;**70**:87–94.
- 45 Weaver JJ, Chick JFB, Monroe EJ, Johnson GE. Life and limb: current concepts in endovascular treatment of extremity trauma. *Semin Intervent Radiol* 2021;**38**:64–74.
- 46 Richmond BK, Judhan R, Sherrill W, Yacoub M, AbuRahma AF, Knackstedt K, et al. Trends and outcomes in the operative management of traumatic vascular injuries: a comparison of

- open versus endovascular approaches. *Am Surg* 2017;**83**:495–501.
- 47 Dell MCO, Shah J, Martin JG, Kies D. Emergent endovascular treatment of penetrating trauma: solid organ and extremity. *Tech Vasc Interv Radiol* 2017;**20**:243–7.
  - 48 Ptohis ND, Charalampopoulos G, Abou Ali AN, Avgerinos ED, Mousogianni I, Filippiadis D, et al. Contemporary role of embolization of solid organ and pelvic injuries in polytrauma patients. *Front Surg* 2017;**4**:43.
  - 49 Demetriades D, Velmahos GC, Scalea TM, Jurkovich GJ, Karmy-Jones R, American Association for the Surgery of Trauma Thoracic Aortic Injury Study Group, et al. Operative repair or endovascular stent graft in blunt traumatic thoracic aortic injuries: results of an American Association for the Surgery of Trauma multicenter study. *J Trauma* 2008;**64**:561–70; discussion 570–1.
  - 50 Reuben BC, Whitten MG, Sarfati M, Kraiss LW. Increasing use of endovascular therapy in acute arterial injuries: analysis of the National Trauma Data Bank. *J Vasc Surg* 2007;**46**:1222–6.
  - 51 Karaolanis G, Moris D, McCoy CC, Tsilimigras DI, Georgopoulos S, Bakoyiannis C. Contemporary strategies in the management of civilian abdominal vascular trauma. *Front Surg* 2018;**5**:7.
  - 52 Stonko DP, Azar FK, Betzold RD, Morrison JJ, Fransman RB, Holcomb J, et al. Contemporary management and outcomes of injuries to the inferior vena cava: a prospective multicenter trial from PROspective Observational Vascular Injury Treatment. *Am Surg* 2023;**89**:714–19.
  - 53 Branco BC, Boutros ML, DuBose JJ, Leake SS, Charlton-Ouw K, Rhee P, et al. Outcome comparison between open and endovascular management of axillosubclavian arterial injuries. *J Vasc Surg* 2016;**63**:702–19.
  - 54 DuBose JJ, Savage SA, Fabian TC, Menaker J, Scalea T, AAST PROOVIT Study Group, et al. The American Association for the Surgery of Trauma PROspective Observational Vascular Injury Treatment (PROOVIT) registry: multicenter data on modern vascular injury diagnosis, management, and outcomes. *J Trauma Acute Care Surg* 2015;**78**:215–22; discussion 222–3.
  - 55 Loftus TJ, Croft CA, Rosenthal MD, Mohr AM, Efron PA, Moore FA, et al. Clinical impact of a dedicated trauma hybrid operating room. *J Am Coll Surg* 2021;**232**:560–70.
  - 56 Khoo CY, Liew TYS, Mathur S. Systematic review of the efficacy of a hybrid operating theatre in the management of severe trauma. *World J Emerg Surg* 2021;**16**:43.
  - 57 Cannon JW, Khan MA, Raja AS, Cohen MJ, Como JJ, Cotton BA, et al. Damage control resuscitation in patients with severe traumatic hemorrhage: a practice management guideline from the Eastern Association for the Surgery of Trauma. *J Trauma Acute Care Surg* 2017;**82**:605–17.
  - 58 Holcomb JB, Tilley BC, Baraniuk S, Fox EE, Wade CE, PROPPR Study Group, et al. Transfusion of plasma, platelets, and red blood cells in a 1:1:1 vs a 1:1:2 ratio and mortality in patients with severe trauma: the PROPPR randomized clinical trial. *JAMA* 2015;**313**:471–82.
  - 59 Sperry JL, Guyette FX, Brown JB, Yazer MH, Triulzi DJ, PAMPer Study Group, et al. Prehospital plasma during air medical transport in trauma patients at risk for hemorrhagic shock. *N Engl J Med* 2018;**379**:315–26.
  - 60 Chee YE, Liu SE, Irwin MG. Management of bleeding in vascular surgery. *Br J Anaesth* 2016;**117**(Suppl. 2):ii85–94.
  - 61 Karl V, Thorn S, Mathes T, Hess S, Maegele M. Association of tranexamic acid administration with mortality and thromboembolic events in patients with traumatic injury: a systematic review and meta-analysis. *JAMA Netw Open* 2022;**5**:220625.
  - 62 Taeuber I, Weibel S, Herrmann E, Neef V, Schlesinger T, Kranke P, et al. Association of intravenous tranexamic acid with thromboembolic events and mortality: a systematic review, meta-analysis, and meta-regression. *JAMA Surg* 2021;**156**:210884.
  - 63 Rivas L, Estroff J, Sparks A, Nahmias J, Allen R, Smith SR, et al. The incidence of venous thromboembolic events in trauma patients after tranexamic acid administration: an EAST multicenter study. *Blood Coagul Fibrinolysis* 2021;**32**:37–43.
  - 64 CRASH-2 Collaborators, Roberts I, Shakur H, Afolabi A, Brohi K, Coats T, et al. The importance of early treatment with tranexamic acid in bleeding trauma patients: an exploratory analysis of the CRASH-2 randomised controlled trial. *Lancet* 2011;**377**:1096–101. 1101.e1–1101.
  - 65 Fouche PF, Stein C, Nichols M, Meadley B, Bendall JC, Smith K, et al. Tranexamic acid for traumatic injury in the emergency setting: a systematic review and bias-adjusted meta-analysis of randomized controlled trials. *Ann Emerg Med* 2024;**83**:435–45.
  - 66 Asaadi S, Mukherjee K, Abou-Zamzam AM, Ji L, Luo-Owen X, AAST PROOVIT Study Group, et al. Tranexamic acid is not associated with a higher rate of thrombotic-related reintervention after major vascular injury repair. *J Trauma Acute Care Surg* 2024;**96**:596–602.
  - 67 Ker K, Roberts I, Shakur H, Coats TJ. Antifibrinolytic drugs for acute traumatic injury. *Cochrane Database Syst Rev* 2015;**2015**(5):CD004896.
  - 68 Cole E, Davenport R, Willett K, Brohi K. Tranexamic acid use in severely injured civilian patients and the effects on outcomes: a prospective cohort study. *Ann Surg* 2015;**261**:390–4.
  - 69 Scerbo MH, Holcomb JB, Taub E, Gates K, Love JD, Wade CE, et al. The trauma center is too late: major limb trauma without a pre-hospital tourniquet has increased death from hemorrhagic shock. *J Trauma Acute Care Surg* 2017;**83**:1165–72.
  - 70 Beekley AC, Sebesta JA, Blackburne LH, Herbert GS, Kauvar DS, 31st Combat Support Hospital Research Group, et al. Prehospital tourniquet use in Operation Iraqi Freedom: effect on hemorrhage control and outcomes. *J Trauma* 2008;**64**(2 Suppl.):S28–37.
  - 71 Covey DC, Gentchos CE. Field tourniquets in an austere military environment: a prospective case series. *Injury* 2022;**53**:3240–7.
  - 72 Benítez CY, Ottolino P, Pereira BM, Lima DS, Guemes A, Khan M, et al. Tourniquet use for civilian extremity hemorrhage: systematic review of the literature. *Rev Col Bras Cir* 2021;**48**:e20202783.
  - 73 Teixeira PGR, Brown CVR, Emigh B, Long M, Foreman M, Texas Tourniquet Study Group, et al. Civilian prehospital tourniquet use is associated with improved survival in patients with peripheral vascular injury. *J Am Coll Surg* 2018;**226**:769–76.e1.
  - 74 Henry R, Matsushima K, Ghafil C, Henry RN, Theeuwens H, Golden AC, et al. Increased use of prehospital tourniquet and patient survival: Los Angeles countywide study. *J Am Coll Surg* 2021;**233**:233–9.e2.
  - 75 Smith AA, Ochoa JE, Wong S, Beatty S, Elder J, Guidry C, et al. Prehospital tourniquet use in penetrating extremity trauma: decreased blood transfusions and limb complications. *J Trauma Acute Care Surg* 2019;**86**:43–51.
  - 76 Eilertsen KA, Winberg M, Jeppesen E, Hval G, Wisborg T. Prehospital tourniquets in civilians: a systematic review. *Prehosp Disaster Med* 2021;**36**:86–94.
  - 77 Holcomb JB, Dorlac WC, Drew BG, Butler FK, Gurney JM, Montgomery HR, et al. Rethinking limb tourniquet conversion in the prehospital environment. *J Trauma Acute Care Surg* 2023;**95**:e54–60.
  - 78 Cannon JW. Hemorrhagic shock. *N Engl J Med* 2018;**378**:1852–3.
  - 79 Marsden M, Lendrum R, Davenport R. Revisiting the promise, practice and progress of resuscitative endovascular balloon occlusion of the aorta. *Curr Opin Crit Care* 2023;**29**:689–95.
  - 80 Maiga AW, Kundi R, Morrison JJ, Spalding C, Duchesne J, Hunt J, et al. Systematic review to evaluate algorithms for REBOA use in trauma and identify a consensus for patient selection. *Trauma Surg Acute Care Open* 2022;**7**:e000984.

- 81 Jansen JO, Hudson J, Cochran C, MacLennan G, Lendrum R, Sadek S, et al. Emergency department resuscitative endovascular balloon occlusion of the aorta in trauma patients with exsanguinating hemorrhage: the UK-REBOA randomized clinical trial. *JAMA* 2023;330:1862–71.
- 82 Shum-Tim L, Bichara-Allard S, Hopkins B, AlShahwan N, Hanley S, Manzano-Nunez R, et al. Vascular access complications associated with resuscitative endovascular balloon occlusion of the aorta in adult trauma patients: a systematic review and meta-analysis. *J Trauma Acute Care Surg* 2024;96:499–509.
- 83 Foley MP, Walsh SR, Doolan N, Vulliamy P, McMonagle M, Aylwin C. Editor's Choice – Systematic review and meta-analysis of lower extremity vascular complications after arterial access for resuscitative endovascular balloon occlusion of the aorta (REBOA): an inevitable concern? *Eur J Vasc Endovasc Surg* 2023;66:103–18.
- 84 Tisherman SA, Brenner ML. Contemporary adjuncts to hemorrhage control. *JAMA* 2023;330:1849–51.
- 85 Martínez Hernández A, Chorro R, Climent A, Lazaro-Paulina FG, Martínez García V. Has the balloon really burst? Analysis of "the UK-REBOA randomized clinical trial". *Am J Surg* 2024;234:62–7.
- 86 Adibi A, Krishnam MS, Dissanayake S, Plotnik AN, Mohajer K, Arellano C, et al. Computed tomography angiography of lower extremities in the emergency room for evaluation of patients with gunshot wounds. *Eur Radiol* 2014;24:1586–93.
- 87 Anderson SW, Foster BR, Soto JA. Upper extremity CT angiography in penetrating trauma: use of 64-section multidetector CT. *Radiology* 2008;249:1064–73.
- 88 Bhalla D, Kumar A, Gamanagatti S, Sagar S, Kumar S, Gupta A. Imaging in extremity vascular trauma: can MDCT angiography predict the nature of injury? *Emerg Radiol* 2022;29:683–90.
- 89 Branco BC, Linnebur M, Boutrous ML, Leake SS, Inaba K, Charlton-Ouw KM, et al. The predictive value of multidetector CTA on outcomes in patients with below-the-knee vascular injury. *Injury* 2015;46:1520–6.
- 90 Foster BR, Anderson SW, Uyeda JW, Brooks JG, Soto JA. Integration of 64-detector lower extremity CT angiography into whole-body trauma imaging: feasibility and early experience. *Radiology* 2011;261:787–95.
- 91 Hogan AR, Lineen EB, Perez EA, Neville HL, Thompson WR, Sola JE. Value of computed tomographic angiography in neck and extremity pediatric vascular trauma. *J Pediatr Surg* 2009;44:1236–41.
- 92 Inaba K, Potzman J, Munera F, McKenney M, Munoz R, Rivas L, et al. Multi-slice CT angiography for arterial evaluation in the injured lower extremity. *J Trauma* 2006;60:502–6.
- 93 Inaba K, Branco BC, Reddy S, Park JJ, Green D, Plurad D, et al. Prospective evaluation of multidetector computed tomography for extremity vascular trauma. *J Trauma* 2011;70:808–15.
- 94 Jens S, Kerstens MK, Legemate DA, Reekers JA, Bipat S, Koelemay MJ. Diagnostic performance of computed tomography angiography in peripheral arterial injury due to trauma: a systematic review and meta-analysis. *Eur J Vasc Endovasc Surg* 2013;46:329–37.
- 95 Patterson BO, Holt PJ, Cleanthis M, Tai N, Carrell T, London Vascular Injuries Working Group, et al. Imaging vascular trauma. *Br J Surg* 2012;99:494–505.
- 96 Romagnoli AN, DuBose J, Dua A, Betzold R, Bee T, AAST PROOVIT Study Group, et al. Hard signs gone soft: a critical evaluation of presenting signs of extremity vascular injury. *J Trauma Acute Care Surg* 2021;90:1–10.
- 97 Fox N, Rajani RR, Bokhari F, Chiu WC, Kerwin A, Eastern Association for the Surgery of Trauma, et al. Evaluation and management of penetrating lower extremity arterial trauma: an Eastern Association for the Surgery of Trauma practice management guideline. *J Trauma Acute Care Surg* 2012;73(5 Suppl. 4):S315–20.
- 98 Walkoff L, Nagpal P, Khandelwal A. Imaging primer for CT angiography in peripheral vascular trauma. *Emerg Radiol* 2021;28:143–52.
- 99 Hsu MJ, Gupta A, Soto JA, LeBedis CA. Imaging of torso and extremity vascular trauma. *Semin Roentgenol* 2016;51:165–79.
- 100 Weisbord SD, Mor MK, Resnick AL, Hartwig KC, Palevsky PM, Fine MJ. Incidence and outcomes of contrast-induced AKI following computed tomography. *Clin J Am Soc Nephrol* 2008;3:1274–81.
- 101 Stengel D, Leisterer J, Ferrada P, Ekkernkamp A, Mutze S, Hoening A. Point-of-care ultrasonography for diagnosing thoracoabdominal injuries in patients with blunt trauma. *Cochrane Database Syst Rev* 2018;12:CD012669.
- 102 Savoia P, Jayanthi SK, Chammas MC. Focused Assessment with Sonography for Trauma (FAST). *J Med Ultrasound* 2023;31:101–6.
- 103 Do WS, Chang R, Fox EE, Wade CE, Holcomb JB, NCTH Study Group, et al. Too fast, or not fast enough? The FAST exam in patients with non-compressible torso hemorrhage. *Am J Surg* 2019;217:882–6.
- 104 Tisherman SA. Management of major vascular injury: open. *Otolaryngol Clin North Am* 2016;49:809–17.
- 105 Doody O, Given MF, Lyon SM. Extremities—indications and techniques for treatment of extremity vascular injuries. *Injury* 2008;39:1295–303.
- 106 Percival TJ, Rasmussen TE. Reperfusion strategies in the management of extremity vascular injury with ischaemia. *Br J Surg* 2012;99(Suppl. 1):66–74.
- 107 Alarhayem AQ, Cohn SM, Cantu-Nunez O, Eastridge BJ, Rasmussen TE. Impact of time to repair on outcomes in patients with lower extremity arterial injuries. *J Vasc Surg* 2019;69:1519–23.
- 108 Vuoncino M, Scheidt J, Kauvar DS. Association between time to revascularization and limb loss in military femoropopliteal arterial injuries. *J Vasc Surg* 2023;78:1198–203.
- 109 Feliciano DV, Subramanian A. Temporary vascular shunts. *Eur J Trauma Emerg Surg* 2013;39:553–60.
- 110 Feliciano DV. Pitfalls in the management of peripheral vascular injuries. *Trauma Surg Acute Care Open* 2017;2:e000110.
- 111 Tung L, Leonard J, Lawless RA, Cralley A, Betzold R, Pasley JD. Temporary intravascular shunts after civilian arterial injury: a prospective multicenter Eastern Association for the Surgery of Trauma study. *Injury* 2021;52:1204–9.
- 112 Borut LT, Acosta CJ, Tadlock LC, Dye JL, Galarneau M, Elshire CD. The use of temporary vascular shunts in military extremity wounds: a preliminary outcome analysis with 2-year follow-up. *J Trauma* 2010;69:174–8.
- 113 Subramanian A, Vercruyse G, Dente C, Wyrzykowski A, King E, Feliciano DV. A decade's experience with temporary intravascular shunts at a civilian level I trauma center. *J Trauma* 2008;65:316–26.
- 114 D'Alleyrand JC, Dutton RP, Pollak AN. Extrapolation of battlefield resuscitative care to the civilian setting. *J Surg Orthop Adv* 2010;19:62–9.
- 115 Allen CJ, Straker RJ, Tashiro J, Teisch LF, Meizoso JP, Ray JJ, et al. Pediatric vascular injury: experience of a level 1 trauma center. *J Surg Res* 2015;196:1–7.
- 116 Inaba K, Aksoy H, Seamon MJ, Marks JA, Duchesne J, Multicenter Shunt Study Group, et al. Multicenter evaluation of temporary intravascular shunt use in vascular trauma. *J Trauma Acute Care Surg* 2016;80:359–64; discussion 364–5.
- 117 Polcz JE, White JM, Ronaldi AE, Dubose JJ, Grey S, Bell D, et al. Temporary intravascular shunt use improves early limb salvage after extremity vascular injury. *J Vasc Surg* 2021;73:1304–13.
- 118 Laverty RB, Treffalls RN, Kauvar DS. Systematic review of temporary intravascular shunt use in military and civilian extremity trauma. *J Trauma Acute Care Surg* 2022;92:232–8.



- 119 Rasmussen TE, Clouse WD, Jenkins DH, Peck MA, Eliason JL, Smith DL. The use of temporary vascular shunts as a damage control adjunct in the management of wartime vascular injury. *J Trauma* 2006;**61**:8–12; discussion 12–15.
- 120 Hornez E, Boddaert G, Ngabou UD, Aguir S, Baudoin Y, Mocellin N, et al. Temporary vascular shunt for damage control of extremity vascular injury: a toolbox for trauma surgeons. *J Vasc Surg* 2015;**152**:363–8.
- 121 Barros D'Sa AA, Harkin DW, Blair PH, Hood JM, McIlrath E. The Belfast approach to managing complex lower limb vascular injuries. *Eur J Vasc Endovasc Surg* 2006;**32**:246–56.
- 122 Oliver JC, Gill H, Nicol AJ, Edu S, Navsaria PH. Temporary vascular shunting in vascular trauma: a 10-year review from a civilian trauma centre. *S Afr J Surg* 2013;**51**:6–10.
- 123 Mathew S, Smith BP, Cannon JW, Reilly PM, Schwab CW, Seamon MJ. Temporary arterial shunts in damage control: experience and outcomes. *J Trauma Acute Care Surg* 2017;**82**:512–7.
- 124 Ray HM, Sandhu HK, Meyer DE, Miller CC 3rd, Vowels TJ, Afifi RO, et al. Predictors of poor outcome in infrainguinal bypass for trauma. *J Vasc Surg* 2019;**70**:1816–22.
- 125 Mohammadzade MA, Mohammadzade M, Herfatkar MR. A comparison of interposition and femoropopliteal bypass grafts in the management of popliteal artery trauma. *Iran J Med Sci* 2011;**36**:32–5.
- 126 Aksoy M, Tunca F, Yanar H, Guloglu R, Ertekin C, Kurtoglu M. Traumatic injuries to the subclavian and axillary arteries: a 13-year review. *Surg Today* 2005;**35**:561–5.
- 127 Yagubyan M, Panneton JM. Axillary artery injury from humeral neck fracture: a rare but disabling traumatic event. *Vasc Endovascular Surg* 2004;**38**:175–84.
- 128 Flis V, Tomazic T. Complex vascular injuries of lower limbs in children. *Zdrav Vestn* 2007;**76**:467–72.
- 129 Stain SC, Weaver FA, Yellin AE. Extra-anatomic bypass of failed traumatic arterial repairs. *J Trauma* 1991;**31**:575–8.
- 130 Karmy-Jones R, DuBose R, King S. Traumatic rupture of the innominate artery. *Eur J Cardiothorac Surg* 2003;**23**:782–7.
- 131 Lyons NB, Berg A, Collie BL, Meizoso JP, Sola JE, Thorson CM, et al. Management of lower extremity vascular injuries in pediatric trauma patients: 20-year experience at a level 1 trauma center. *Trauma Surg Acute Care Open* 2024;**9**:e001263.
- 132 Hafez HM, Woolgar J, Robbs JV. Lower extremity arterial injury: results of 550 cases and review of risk factors associated with limb loss. *J Vasc Surg* 2001;**33**:1212–9.
- 133 Lakhwani MN, Gooi BH, Barras CD. Vascular trauma in Penang and Kuala Lumpur hospitals. *Med J Malaysia* 2002;**57**:426–32.
- 134 Pary NG, Feliciano DV, Burke RM, Cava RA, Nicholas JM, Dente CJ, et al. Management and short-term patency of lower extremity venous injuries with various repairs. *Am J Surg* 2003;**186**:631–5.
- 135 Stonko DP, Betzold RD, Abdou H, Edwards J, Azar FK, AAST PROOVIT Study Group, et al. In-hospital outcomes in autogenous vein versus synthetic graft interposition for traumatic arterial injury: a propensity-matched cohort from PROOVIT. *J Trauma Acute Care Surg* 2022;**92**:407–12.
- 136 Watson JDB, Houston R 4th, Morrison JJ, Gifford SM, Rasmussen TE. A retrospective cohort comparison of expanded polytetrafluorethylene to autologous vein for vascular reconstruction in modern combat casualty care. *Ann Vasc Surg* 2015;**29**:822–9.
- 137 Reilly B, Khan S, Dosluoglu H, Harris L, O'Brien-Irr M, Lukan J, et al. Comparison of autologous vein and bovine carotid artery graft as a bypass conduit in arterial trauma. *Ann Vasc Surg* 2019;**61**:246–53.
- 138 Ur Rehman Z. Outcomes of popliteal artery injuries repair: autologous vein versus prosthetic interposition grafts. *Ann Vasc Surg* 2020;**69**:141–5.
- 139 Vertrees A, Fox CJ, Quan RW, Cox MW, Adams ED, Gillespie DL. The use of prosthetic grafts in complex military vascular trauma: a limb salvage strategy for patients with severely limited autologous conduit. *J Trauma* 2009;**66**:980–3.
- 140 Forsyth A, Haqqani MH, Alfson DB, Shaikh SP, Brea F, Richman A, et al. Long-term outcomes of autologous vein bypass for repair of upper and lower extremity major arterial trauma. *J Vasc Surg* 2024;**79**:1339–46.
- 141 Kim S, Schneider A, Raulli S, Ruiz C, Marston W, McGinagle KL, et al. Current outcomes following upper and lower extremity arterial trauma from the National Trauma Data Bank. *J Vasc Surg* 2024;**80**:365–72.e1.
- 142 Williams TK, Clouse WD. Current concepts in repair of extremity venous injury. *J Vasc Surg Venous Lymphat Disord* 2016;**4**:238–47.
- 143 Sokolov O, Shaprynskiy V, Skupyy O, Stanko O, Yurets S, Yurkova Y, et al. Use of bioengineered human acellular vessels to treat traumatic injuries in the Ukraine–Russia conflict. *Lancet Reg Health Eur* 2023;**29**:100650.
- 144 Reddy NP, Rowe VL. Is it really mandatory to harvest the contralateral saphenous vein for use in repair of traumatic injuries? *Vasc Endovascular Surg* 2018;**52**:548–9.
- 145 Shaikh SP, Haqqani MH, Alfson DB, Forsyth A, Brea F, Richman A, et al. Outcomes following ipsilateral great saphenous vein bypass for lower extremity arterial injuries. *Injury* 2023; doi: 10.1016/j.injury.2023.03.030 [epub ahead of print].
- 146 Siddiqi N, Lammers D, Hu P, Stonko D, DuBose J, Hurst S, et al. Comparison of contralateral vs ipsilateral vein graft for traumatic vascular injury repair: a cohort from PROOVIT. *Am Surg* 2024;**90**:2310–3.
- 147 Madsen AS, Kruger D, Clarke DL, Navsaria P, Scriba M, Bekker W, et al. Outcomes of penetrating carotid artery injuries: a South African multicentre study. *World J Surg* 2024;**48**:1848–62.
- 148 Inaba K, Munera F, McKenney MG, Rivas L, Marecos E, de Moya M, et al. The nonoperative management of penetrating internal jugular vein injury. *J Vasc Surg* 2006;**43**:77–80.
- 149 Nowicki JL, Stew B, Ooi E. Penetrating neck injuries: a guide to evaluation and management. *Ann R Coll Surg Engl* 2018;**100**:6–11.
- 150 Asensio JA, Dabestani PJ, Wenzl FA, Miljkovic SS, Kessler JJ 2nd, Fernández CA, et al. A systematic review of penetrating extracranial vertebral artery injuries. *J Vasc Surg* 2020;**71**:2161–9.
- 151 Alao T, Waseem M. Neck trauma. In: *StatPearls*. Treasure Island, FL: StatPearls Publishing; 2023.
- 152 Low GMI, Inaba K, Chouliaras K, Branco B, Lam L, Benjamin E, et al. The use of the anatomic 'zones' of the neck in the assessment of penetrating neck injury. *Am Surg* 2014;**80**:970–4.
- 153 Ko JW, Gong SC, Kim MJ, Chung JS, Choi YU, Lee JH, et al. The efficacy of the "no zone" approach for the assessment of traumatic neck injury: a case–control study. *Ann Surg Treat Res* 2020;**99**:352–61.
- 154 Shiroff AM, Gale SC, Martin ND, Marchalik D, Petrov D, Ahmed HM, et al. Penetrating neck trauma: a review of management strategies and discussion of the 'no zone' approach. *Am Surg* 2013;**79**:23–9.
- 155 Ibraheem K, Wong S, Smith A, Guidry C, McGrew P, McGinness C, et al. Computed tomography angiography in the "no-zone" approach era for penetrating neck trauma: a systematic review. *J Trauma Acute Care Surg* 2020;**89**:1233–8.
- 156 Chandrananth ML, Zhang A, Voutier CR, Skandarajah A, Thomson BNJ, Shakerian R, et al. 'No zone' approach to the management of stable penetrating neck injuries: a systematic review. *ANZ J Surg* 2021;**91**:1083–90.
- 157 Bell RB, Osborn T, Dierks EJ, Potter BE, Long WB. Management of penetrating neck injuries: a new paradigm for civilian trauma. *J Oral Maxillofac Surg* 2007;**65**:691–705.
- 158 Tisherman SA, Bokhari F, Collier B, Cumming J, Ebert J, Holevar M, et al. Clinical practice guideline: penetrating zone II neck trauma. *J Trauma* 2008;**64**:1392–405.
- 159 Sperry JL, Moore EE, Coimbra R, Croce M, Davis JW, Karmy-Jones R, et al. Western Trauma Association critical decisions in

- trauma: penetrating neck trauma. *J Trauma Acute Care Surg* 2013;**75**:936–40.
- 160 Brywczyński JJ, Barrett TW, Lyon JA, Cotton BA. Management of penetrating neck injury in the emergency department: a structured literature review. *Emerg Med J* 2008;**25**:711–5.
- 161 Serna JJ, Ordoñez CA, Parra MW, Serna C, Caicedo Y, Rosero A, et al. Damage control in penetrating carotid artery trauma: changing a 100-year paradigm. *Colomb Med (Cali)* 2021;**52**:e4054807.
- 162 Karagiorgas GP, Brotis AG, Giannis T, Rountas CD, Vassiou KG, Fountas KN, et al. The diagnostic accuracy of magnetic resonance angiography for blunt vertebral artery injury detection in trauma patients: a systematic review and meta-analysis. *Clin Neurol Neurosurg* 2017;**160**:152–63.
- 163 Ronaldi AE, Polcz JE, Robertson HT, Walker PF, Bozzay JD, Dubose JJ, et al. A multi-registry analysis of military and civilian penetrating cervical carotid artery injury. *J Trauma Acute Care Surg* 2021;**91**(2S Suppl. 2):S226–32.
- 164 Weinberg JA, Moore AH, Magnotti LJ, Teague RJ, Ward TA, Wasmund JB, et al. Contemporary management of civilian penetrating cervicothoracic arterial injuries. *J Trauma Acute Care Surg* 2016;**81**:302–6.
- 165 White PW, Walker PF, Bozzay JD, Patel JA, Rasmussen TE, White JM. Management and outcomes of wartime cervical carotid artery injury. *J Trauma Acute Care Surg* 2020;**89**(2S Suppl. 2):S225–30.
- 166 McConnell DB, Trunkey DD. Management of penetrating trauma to the neck. *Adv Surg* 1994;**27**:97–127.
- 167 du Toit DF, Coolen D, Lambrechts A, de V Odenaal J, Warren BL. The endovascular management of penetrating carotid artery injuries: long-term follow-up. *Eur J Vasc Endovasc Surg* 2009;**38**:267–72.
- 168 Reva VA, Pronchenko AA, Samokhvalov IM. Operative management of penetrating carotid artery injuries. *Eur J Vasc Endovasc Surg* 2011;**42**:16–20.
- 169 Plotkin A, Weaver FA, Owattanapanich N, Byerly S, Schellenberg M, Inaba K, et al. Epidemiology, repair technique, and predictors of stroke and mortality in penetrating carotid artery injuries. *J Vasc Surg* 2023;**78**:920–8.
- 170 Piper K, Rabil M, Ciesla D, Agazzi S, Ren Z, Mokin M, et al. Penetrating vertebral artery injuries: a literature review and proposed treatment algorithm. *World Neurosurg* 2021;**148**:e518–26.
- 171 Schellenberg M, Owattanapanich N, Cowan S, Strickland M, Lewis M, Clark DH, et al. Penetrating injuries to the vertebral artery: interventions and outcomes from US trauma centers. *Eur J Trauma Emerg Surg* 2022;**48**:481–8.
- 172 AlBayer A, Sullivan PZ, Blue R, Leonard J, Kung DK, Ozturk AK, et al. Risk of vertebral artery injury and stroke following blunt and penetrating cervical spine trauma: a retrospective review of 729 patients. *World Neurosurg* 2019;**130**:e672–9.
- 173 Karatela M, Weissler EH, Cox MW, Williams ZF. Vertebral artery transection with pseudoaneurysm and arteriovenous fistula requiring antegrade and retrograde embolization. *J Vasc Surg Cases Innov Tech* 2022;**8**:183–6.
- 174 Nonaka S, Oishi H, Tsutsumi S, Ishii H. Traumatic cervical vertebral artery aneurysm associated with suicidal stabs. *Surg Neurol Int* 2021;**12**:452.
- 175 Tong TMC, Wong OF, Kwan GWM, Chan KKC. A case of penetrating neck injury with retained foreign body in the cervical vertebral body and vertebral artery dissection. *Hong Kong J Emerg Med* 2017;**24**:148–53.
- 176 Murakami M, Maruyama D, Fujiwara G, Komaru Y, Murakami N, Iiduka R. Early treatment of progressive vertebral arteriovenous fistula caused by cervical penetrating injury. *Acute Med Surg* 2020;**7**:e467.
- 177 Yaguchi S, Yamamura H, Kamata K, Shimamura N, Kakehata S, Matsubara A. Treatment strategy for a penetrating stab wound to the vertebral artery: a case report. *Acute Med Surg* 2019;**6**:83–6.
- 178 Leiderman DBD, Zerati AE, Wolosker N, Hoffmann Melo HA, Simão de Silva E, De Luccia N. Endovascular treatment of penetrating injury to the vertebral artery by a stab wound: case report and literature review. *Ann Vasc Surg* 2017;**45**:267.e1–5.
- 179 Mizuno K, Shinohara S, Omura Y, Imamura H, Shigeyasu M, Michida T, et al. Vertebral artery injury caused by glass remnants in the neck: a case report. *Acta Otolaryngol Case Rep* 2019;**4**:30–4.
- 180 Lam Y-Y, Tsui H-F, Wong H-L, Chow Y-Y. Management approach of penetrating vertebral artery injury with concomitant cervical nerve root injury in regional hospital: report of two cases. *Journal of Orthopaedics, Trauma and Rehabilitation* 2018;**25**:5–10.
- 181 Demetriades D, Theodorou D, Asensio J, Golshani S, Belzberg H, Yellin A, et al. Management options in vertebral artery injuries. *Br J Surg* 1996;**83**:83–6.
- 182 Yee LF, Olcott EW, Knudson MM, Lim RC Jr. Extraluminal, transluminal and observational treatment for vertebral artery injuries. *J Trauma* 1995;**39**:480–4; discussion 484–6.
- 183 Albuquerque FC, Javedan SP, McDougall CG. Endovascular management of penetrating vertebral artery injuries. *J Trauma* 2002;**53**:574–80.
- 184 Uchikawa H, Kai Y, Ohmori Y, Kuratsu J. Strategy for endovascular coil embolization of a penetrating vertebral artery injury. *Surg Neurol Int* 2015;**6**:117.
- 185 Simmons JD, Ahmed N, Donnellan KA, Schmieg RE Jr, Porter JM, Mitchell ME. Management of traumatic vascular injuries to the neck: a 7-year experience at a Level I trauma center. *Am Surg* 2012;**78**:335–8.
- 186 Geddes AE, Burlew CC, Wagenaar AE, Biffi WL, Johnson JL, Pieracci FM, et al. Expanded screening criteria for blunt cerebrovascular injury: a bigger impact than anticipated. *Am J Surg* 2016;**212**:1167–74.
- 187 Grigorian A, Kabutey NK, Schubl S, de Virgilio C, Joe V, Dolich M, et al. Blunt cerebrovascular injury incidence, stroke rate, and mortality with the expanded Denver criteria. *Surgery* 2018;**164**:494–9.
- 188 Esnault P, Cardinale M, Boret H, D'Aranda E, Montcriol A, Bordes J, et al. Blunt cerebrovascular injuries in severe traumatic brain injury: incidence, risk factors and evolution. *J Neurosurg* 2017;**127**:16–22.
- 189 Paulus EM, Fabian TC, Savage SA, Zarzaur BL, Botta V, Dutton W, et al. Blunt cerebrovascular injury screening with 64-channel multidetector computed tomography: more slices finally cut it. *J Trauma Acute Care Surg* 2014;**76**:279–83; discussion 284–5.
- 190 Roberts DJ, Chaubey VP, Zygun DA, Lorenzetti D, Faris PD, Ball CG, et al. Diagnostic accuracy of computed tomographic angiography for blunt cerebrovascular injury detection in trauma patients: a systematic review and meta-analysis. *Ann Surg* 2013;**257**:621–32.
- 191 Biffi WL, Eggin T, Benedetto B, Gibbs F, Cioffi WG. Sixteen-slice computed tomographic angiography is a reliable noninvasive screening test for clinically significant blunt cerebrovascular injuries. *J Trauma* 2006;**60**:745–51; discussion 751–2.
- 192 Brommeland T, Helseth E, Aarhus M, Moen KG, Dyrskog S, Bergholt B, et al. Best practice guidelines for blunt cerebrovascular injury (BCVI). *Scand J Trauma Resus Emerg Med* 2018;**26**:90.
- 193 Biffi WL, Moore EE, Offner PJ, Brega KE, Franciose RJ, Elliott JP, et al. Optimizing screening for blunt cerebrovascular injuries. *Am J Surg* 1999;**178**:517–22.
- 194 Biffi WL, Cothren CC, Moore EE, Kozar R, Cocanour C, Davis JW. Western Trauma Association critical decisions in trauma: screening for and treatment of blunt cerebrovascular injuries. *J Trauma* 2009;**67**:1150–3.
- 195 Jacobson LE, Ziemba-Davis M, Herrera AJ. The limitations of using risk factors to screen for blunt cerebrovascular injuries: the harder you look, the more you find. *World J Emerg Surg* 2015;**10**:46.
- 196 Leichtle SW, Banerjee D, Schrader R, Torres B, Jayaraman S, Rodas E, et al. Blunt cerebrovascular injury: the case for universal screening. *J Trauma Acute Care Surg* 2020;**89**:880–6.

- 197 Black JA, Abraham PJ, Abraham MN, Cox DB, Griffin RL, Holcomb JB, et al. Universal screening for blunt cerebrovascular injury. *J Trauma Acute Care Surg* 2021;**90**:224–31.
- 198 Bruns BR, Tesoriero R, Kufera J, Sliker C, Laser A, Scalea TM, et al. Blunt cerebrovascular injury screening guidelines: what are we willing to miss? *J Trauma Acute Care Surg* 2014;**76**:691–5.
- 199 McNutt MK, Kale AC, Kitagawa RS, Turkmani AH, Fields DW, Baraniuk S, et al. Management of blunt cerebrovascular injury (BCVI) in the multisystem injury patient with contraindications to immediate anti-thrombotic therapy. *Injury* 2018;**49**:67–74.
- 200 Biffl WL, Ray CE Jr, Moore EE, Franciose RJ, Aly S, Heyrosa MG, et al. Treatment-related outcomes from blunt cerebrovascular injuries: importance of routine follow-up arteriography. *Ann Surg* 2002;**235**:699–706; discussion 706–7.
- 201 Russo RM, Davidson AJ, Alam HB, DuBose JJ, Galante JM, AAST PROOVIT Study Group, et al. Blunt cerebrovascular injuries: outcomes from the American Association for the Surgery of Trauma PROspective Observational Vascular Injury Treatment (PROOVIT) multicenter registry. *J Trauma Acute Care Surg* 2021;**90**:987–95.
- 202 Murphy PB, Severance S, Holler E, Menard L, Savage S, Zarzaur BL. Treatment of asymptomatic blunt cerebrovascular injury (BCVI): a systematic review. *Trauma Surg Acute Care Open* 2021;**6**:e000668.
- 203 Shahan CP, Magnotti LJ, McBeth PB, Weinberg JA, Croce MA, Fabian TC. Early antithrombotic therapy is safe and effective in patients with blunt cerebrovascular injury and solid organ injury or traumatic brain injury. *J Trauma Acute Care Surg* 2016;**81**:173–7.
- 204 Momic J, Yassin N, Kim MY, Walser E, Smith S, Ball I, et al. Antiplatelets versus anticoagulants in the treatment of blunt cerebrovascular injury (BCVI) – a systematic review and meta-analysis. *Injury* 2024;**55**:111485.
- 205 Wagenaar AE, Burlew CC, Biffl WL, Beauchamp KM, Pieracci FM, Stovall RT, et al. Early repeat imaging is not warranted for high-grade blunt cerebrovascular injuries. *J Trauma Acute Care Surg* 2014;**77**:540–5; quiz 650.
- 206 Franz RW, Goodwin RB, Beery PR 2nd, Hari JK, Hartman JF, Wright ML. Postdischarge outcomes of blunt cerebrovascular injuries. *Vasc Endovascular Surg* 2010;**44**:198–211.
- 207 DuBose J, Recinos G, Teixeira PG, Inaba K, Demetriades D. Endovascular stenting for the treatment of traumatic internal carotid injuries: expanding experience. *J Trauma* 2008;**65**:1561–6.
- 208 Shahan CP, Sharpe JP, Stickley SM, Manley NR, Filiberto DM, Fabian TC, et al. The changing role of endovascular stenting for blunt cerebrovascular injuries. *J Trauma Acute Care Surg* 2018;**84**:308–11.
- 209 Lauerman MH, Feeney T, Sliker CW, Saksobhavit N, Bruns BR, Laser A, et al. Lethal now or lethal later: the natural history of grade 4 blunt cerebrovascular injury. *J Trauma Acute Care Surg* 2015;**78**:1071–4; discussion 1704–5.
- 210 Kim DY, Biffl W, Bokhari F, Brakenridge S, Chao E, Claridge JA, et al. Evaluation and management of blunt cerebrovascular injury: a practice management guideline from the Eastern Association for the Surgery of Trauma. *J Trauma Acute Care Surg* 2020;**88**:875–87.
- 211 Mei Q, Sui M, Xiao W, Sun Z, Bai R, Huang C, et al. Individualized endovascular treatment of high-grade traumatic vertebral artery injury. *Acta Neurochir (Wien)* 2014;**156**:1781–8.
- 212 Burlew CC, Biffl WL, Moore EE, Pieracci FM, Beauchamp KM, Stovall R, et al. Endovascular stenting is rarely necessary for the management of blunt cerebrovascular injuries. *J Am Coll Surg* 2014;**218**:1012–7.
- 213 DiCocco JM, Fabian TC, Emmett KP, Magnotti LJ, Zarzaur BL, Bate BG, et al. Optimal outcomes for patients with blunt cerebrovascular injury (BCVI): tailoring treatment to the lesion. *J Am Coll Surg* 2011;**212**:549–57; discussion 557–9.
- 214 Patel SD, Haynes R, Satff I, Tunguturi A, Elmoursi S, Nouh A. Recanalization of cervicocephalic artery dissection. *Brain Circ* 2020;**6**:175–80.
- 215 Daou B, Hammer C, Chalouhi N, Starke RM, Jabbour P, Rosenwasser RH, et al. Dissecting pseudoaneurysms: predictors of symptom occurrence, enlargement, clinical outcome, and treatment. *J Neurosurg* 2016;**125**:936–42.
- 216 Crawford JD, Allan KM, Patel KU, Hart KD, Schreiber MA, Azarbal AF, et al. The natural history of indeterminate blunt cerebrovascular injury. *JAMA Surg* 2015;**150**:841–7.
- 217 Ramchand P, Mullen MT, Bress A, Hurst R, Kasner SE, Cucchiara BL, et al. Recanalization after extracranial dissection: effect of antiplatelet compared with anticoagulant therapy. *J Stroke Cerebrovasc Dis* 2018;**27**:438–44.
- 218 Vezzetti A, Rosati LM, Lowe FJ, Graham CB, Moftakhar R, Mangubat E, et al. Stenting as a treatment for cranio-cervical artery dissection: improved major adverse cardiovascular event-free survival. *Catheter Cardiovasc Interv* 2022;**99**:134–9.
- 219 Pham MH, Rahme RJ, Arnaout O, Hurley MC, Bernstein RA, Batjer HH, et al. Endovascular stenting of extracranial carotid and vertebral artery dissections: a systematic review of the literature. *Neurosurgery* 2011;**68**:856–66; discussion 866.
- 220 Markus HS, Levi C, King A, Madigan J, Norris J, Cervical Artery Dissection in Stroke Study (CADISS) Investigators. Antiplatelet therapy vs anticoagulation therapy in Cervical Artery Dissection in Stroke Study (CADISS) randomized clinical trial final results. *JAMA Neurol* 2019;**76**:657–64.
- 221 Rosati LM, Vezzetti A, Redd KT, McMillian B, Giamberardino L, Kodumuri N, et al. Early anticoagulation or antiplatelet therapy is critical in craniocervical artery dissection: results from the COMPASS registry. *Cerebrovasc Dis* 2020;**49**:369–74.
- 222 Daou B, Hammer C, Mouchtouris N, Starke RM, Koduri S, Yang S, et al. Anticoagulation vs antiplatelet treatment in patients with carotid and vertebral artery dissection: a study of 370 patients and literature review. *Neurosurgery* 2017;**80**:368–79.
- 223 Stein DM, Boswell S, Sliker CW, Lui FY, Scalea TM. Blunt cerebrovascular injuries: does treatment always matter? *J Trauma* 2009;**66**:132–43; discussion 143–4.
- 224 Alterman DM, Heidel RE, Daley BJ, Grandas OH, Stevens SL, Goldman MH, et al. Contemporary outcomes of vertebral artery injury. *J Vasc Surg* 2013;**57**:741–6; discussion 746.
- 225 Calcut RA, Hanseman DJ, Solan PD, Kadon KS, Ingalls NK, Fortuna GR, et al. Early treatment of blunt cerebrovascular injury with concomitant hemorrhagic neurologic injury is safe and effective. *J Trauma Acute Care Surg* 2021;**72**:338–45; discussion 345–6.
- 226 Rao AS, Makaroun MS, Marone LK, Cho JS, Rhee R, Chaer RA. Long-term outcomes of internal carotid artery dissection. *J Vasc Surg* 2011;**54**:370–4; discussion 375.
- 227 Paraskevas KI, Batchelder AJ, Naylor AR. Fate of distal false aneurysms complicating internal carotid artery dissection: a systematic review. *Eur J Vasc Endovasc Surg* 2016;**52**:281–6.
- 228 Cothren CC, Moore EE, Ray CE Jr, Ciesla DJ, Johnson JL, Moore JB, et al. Carotid artery stents for blunt cerebrovascular injury: risks exceed benefits. *Arch Surg* 2005;**140**:480–5; discussion 485–6.
- 229 Hershberger RC, Aulivola B, Murphy M, Luchette FA. Endovascular grafts for treatment of traumatic injury to the aortic arch and great vessels. *J Trauma* 2009;**67**:660–71.
- 230 Sun J, Ren K, Zhang L, Xue C, Duan W, Liu J, et al. Traumatic blunt thoracic aortic injury: a 10-year single-center retrospective analysis. *J Cardiothorac Surg* 2022;**17**:335.
- 231 Fabian TC, Richardson JD, Croce MA, Smith JS Jr, Rodman G Jr, Kearney PA, et al. Prospective study of blunt aortic injury: multicenter trial of The American Association for the Surgery of Trauma. *J Trauma* 1997;**42**:374–80; discussion 380–3.
- 232 Neschis DG, Scalea TM, Flinn WR, Griffith BP. Blunt aortic injury. *N Engl J Med* 2008;**359**:1708–16.

- 233 Hemmila MR, Arbabi S, Rowe SA. Delayed repair for blunt thoracic aortic injury: is it really equivalent to early repair? *J Trauma* 2004;**56**:13–23.
- 234 Fabian TC, Davis KA, Gavant ML, Croce MA, Melton SM, Patton JH Jr, et al. Prospective study of blunt aortic injury: helical CT is diagnostic and antihypertensive therapy reduces rupture. *Ann Surg* 1998;**227**:666–76; discussion 676–7.
- 235 Bossone E, Eagle KA. Epidemiology and management of aortic disease: aortic aneurysms and acute aortic syndromes. *Nat Rev Cardiol* 2021;**18**:331–48.
- 236 Gaffey AC, Zhang J, Saka E, Quatromoni JG, Glaser J, Kim P, et al. Natural history of nonoperative management of grade II blunt thoracic aortic injury. *Ann Vasc Surg* 2020;**65**:124–9.
- 237 Osgood MJ, Heck JM, Rellinger EJ, Doran SL, Garrard CL 3rd, Guzman RJ, et al. Natural history of grade I–II blunt traumatic aortic injury. *J Vasc Surg* 2014;**59**:334–41.
- 238 Jacob-Brassard J, Salata K, Kayssi A, Hussain MA, Forbes TL, Al-Omran M, et al. A systematic review of nonoperative management in blunt thoracic aortic injury. *J Vasc Surg* 2019;**70**:1675–1681.e6.
- 239 Lee WA, Matsumura JS, Mitchell RS, Farber MA, Greenberg RK, Azizzadeh A, et al. Endovascular repair of traumatic thoracic aortic injury: clinical practice guidelines of the Society for Vascular Surgery. *J Vasc Surg* 2011;**53**:187–92.
- 240 Arbabi CN, DuBose J, Charlton-Ouw K, Starnes BW, Saqib N, Aortic Trauma Foundation Study Group, et al. Outcomes and practice patterns of medical management of blunt thoracic aortic injury from the Aortic Trauma Foundation global registry. *J Vasc Surg* 2022;**75**:625–31.
- 241 Ultee KH, Soden PA, Chien V, Bensley RP, Zettervall SL, Verhagen HJ, et al. National trends in utilization and outcome of thoracic endovascular aortic repair for traumatic thoracic aortic injuries. *J Vasc Surg* 2016;**63**:1232–9.e1.
- 242 MacKenzie EJ, Rivara FP, Jurkovich GJ, Nathens AB, Frey KP, Egleston BL, et al. A national evaluation of the effect of trauma-center care on mortality. *N Engl J Med* 2006;**354**:366–78.
- 243 Mohapatra A, Liang NL, Makaroun MS, Schermerhorn ML, Farber A, Eslami MH. Improved outcomes of endovascular repair of thoracic aortic injuries at higher volume institutions. *J Vasc Surg* 2021;**73**:1314–9.
- 244 Ekeh AP, Peterson W, Woods RJ, Walusimbi M, Nwuneli N, Saxe JM, et al. Is chest X-ray an adequate screening tool for the diagnosis of blunt thoracic aortic injury? *J Trauma* 2008;**65**:1088–92.
- 245 Demetriades D, Gomez H, Velmahos GC, Asensio JA, Murray J, Cornwell EE 3rd, et al. Routine helical computed tomographic evaluation of the mediastinum in high-risk blunt trauma patients. *Arch Surg* 1998;**133**:1084–8.
- 246 Ho RT, Blackmore CC, Bloch RD, Hoffer EK, Mann FA, Stern EJ, et al. Can we rely on mediastinal widening on chest radiography to identify subjects with aortic injury? *Emerg Radiol* 2002;**9**:183–7.
- 247 Mirvis SE, Shanmuganathan K, Buell J, Rodriguez A. Use of spiral computed tomography for the assessment of blunt trauma patients with potential aortic injury. *J Trauma* 1998;**45**:922–30.
- 248 Parker MS, Matheson TL, Rao AV, Sherbourne CD, Jordan KG, Landay MJ, et al. Making the transition: the role of helical CT in the evaluation of potentially acute thoracic aortic injuries. *AJR Am J Roentgenol* 2001;**176**:1267–72.
- 249 Bruckner BA, DiBardino DJ, Cumbie TC, Trinh C, Blackmon SH, Fisher RG, et al. Critical evaluation of chest computed tomography scans for blunt descending thoracic aortic injury. *Ann Thorac Surg* 2006;**81**:1339–46.
- 250 Gutierrez A, Inaba K, Siboni S, Effron Z, Haltmeier T, Jaffray P, et al. The utility of chest X-ray as a screening tool for blunt thoracic aortic injury. *Injury* 2016;**47**:32–6.
- 251 Downing SW, Sperling JS, Mirvis SE, Cardarelli MG, Gilbert TB, Scalea TM, et al. Experience with spiral computed tomography as the sole diagnostic method for traumatic aortic rupture. *Ann Thorac Surg* 2001;**72**:495–501; discussion 501–2.
- 252 Katayama Y, Kitamura T, Hirose T, Kiguchi T, Matsuyama T, Sado J, et al. Delay of computed tomography is associated with poor outcome in patients with blunt traumatic aortic injury: a nationwide observational study in Japan. *Medicine (Baltimore)* 2018;**97**:e12112.
- 253 Fox N, Schwartz D, Salazar JH, Haut ER, Dahm P, Black JH, et al. Evaluation and management of blunt traumatic aortic injury: a practice management guideline from the Eastern Association for the Surgery of Trauma. *J Trauma Nurs* 2015;**22**:99–110.
- 254 Evangelista A, Sitges M, Jondeau G, Nijveldt R, Pepi M, Cuellar H, et al. Multimodality imaging in thoracic aortic diseases: a clinical consensus statement from the European Association of Cardiovascular Imaging and the European Society of Cardiology working group on aorta and peripheral vascular diseases. *Eur Heart J Cardiovasc Imaging* 2023;**24**:e65–85.
- 255 Azizzadeh A, Charlton-Ouw KM, Chen Z, Rahbar MH, Estrera AL, Amer H, et al. An outcome analysis of endovascular versus open repair of blunt traumatic aortic injuries. *J Vasc Surg* 2013;**57**:108–14; discussion 115.
- 256 Heneghan RE, Aarabi S, Quiroga E, Gunn ML, Singh N, Starnes BW. Call for a new classification system and treatment strategy in blunt aortic injury. *J Vasc Surg* 2016;**64**:171–6.
- 257 Starnes BW, Lundgren RS, Gunn M, Quade S, Hatsukami TS, Tran NT, et al. A new classification scheme for treating blunt aortic injury. *J Vasc Surg* 2012;**55**:47–54.
- 258 Harris DG, Rabin J, Starnes BW, Khoynezhad A, Conway RG, Taylor BS, et al. Evolution of lesion-specific management of blunt thoracic aortic injury. *J Vasc Surg* 2016;**64**:500–5.
- 259 Rabin J, DuBose J, Sliker CW, O'Connor JV, Scalea TM, Griffith BP. Parameters for successful nonoperative management of traumatic aortic injury. *J Thorac Cardiovasc Surg* 2014;**147**:143–9.
- 260 DuBose JJ, Leake SS, Brenner M, Pasley J, O'Callaghan T, Aortic Trauma Foundation, et al. Contemporary management and outcomes of blunt thoracic aortic injury: a multicenter retrospective study. *J Trauma Acute Care Surg* 2015;**78**:360–9.
- 261 Rabin J, Harris DG, Crews GA, Ho M, Taylor BS, Sarkar R, et al. Early aortic repair worsens concurrent traumatic brain injury. *Ann Thorac Surg* 2014;**98**:46–51; discussion 51–2.
- 262 Sandhu HK, Leonard SD, Perlick A, Saqib NU, Miller CC 3rd, Charlton-Ouw KM, et al. Determinants and outcomes of nonoperative management for blunt traumatic aortic injuries. *J Vasc Surg* 2018;**67**:389–98.
- 263 De Freitas S, Joyce D, Yang Y, Dunphy K, Walsh S, Fatima J. Systematic review and meta-analysis of nonoperative management for SVS grade II blunt traumatic aortic injury. *Ann Vasc Surg* 2024;**98**:220–7.
- 264 Yadavalli SD, Romijn AC, Rastogi V, Summers SP, Marcaccio CL, Zettervall SL, et al. Outcomes following thoracic endovascular aortic repair for blunt thoracic aortic injury stratified by Society for Vascular Surgery grade. *J Vasc Surg* 2023;**78**:38–47.e2.
- 265 Soong TK, Wee LJY, Tseng FS, Syn N, Choong AMTL. A systematic review and meta-regression analysis of nonoperative management of blunt traumatic thoracic aortic injury in 2897 patients. *J Vasc Surg* 2019;**70**:941–953.e13.
- 266 Demetriades D, Velmahos GC, Scalea TM, Jurkovich GJ, Karmy-Jones R, Teixeira PG, et al. Blunt traumatic thoracic aortic injuries: early or delayed repair—results of an American Association for the Surgery of Trauma prospective study. *J Trauma* 2009;**66**:967–73.
- 267 Alarhayem AQ, Rasmussen TE, Farivar B, Lim S, Braverman M, Hardy D, et al. Timing of repair of blunt thoracic aortic injuries in the thoracic endovascular aortic repair era. *J Vasc Surg* 2021;**73**:896–902.
- 268 Arbabi CN, DuBose J, Starnes BW, Saqib N, Quiroga E, Aortic Trauma Foundation Study Group, et al. Outcomes of thoracic endovascular aortic repair in patients with concomitant blunt

- thoracic aortic injury and traumatic brain injury from the Aortic Trauma Foundation global registry. *J Vasc Surg* 2022;**75**:930–8.
- 269 Harris DG, Rabin J, Kufera JA, Taylor BS, Sarkar R, O'Connor JV, et al. A new aortic injury score predicts early rupture more accurately than clinical assessment. *J Vasc Surg* 2015;**61**:332–8.
- 270 Estrera AL, Gochnour DC, Azizzadeh A, Miller CC 3rd, Coogan S, Charlton-Ouw K, et al. Progress in the treatment of blunt thoracic aortic injury: 12-year single-institution experience. *Ann Thorac Surg* 2010;**90**:64–71.
- 271 Yadavalli SD, Summers SP, Rastogi V, Romijn AC, Marcaccio CL, Lagazzi E, et al. The impact of urgency of repair on outcomes following thoracic endovascular aortic repair for blunt thoracic aortic injury. *J Vasc Surg* 2024;**79**:229–39.e3.
- 272 Marcaccio CL, Dumas RP, Huang Y, Yang W, Wang GJ, Holena DN. Delayed endovascular aortic repair is associated with reduced in-hospital mortality in patients with blunt thoracic aortic injury. *J Vasc Surg* 2018;**68**:64–73.
- 273 McCurdy CM, Faiza Z, Namburi N, Hartman TJ, Corvera JS, Jenkins P, et al. Eleven-year experience treating blunt thoracic aortic injury at a tertiary referral center. *Ann Thorac Surg* 2020;**110**:524–30.
- 274 Romijn AC, Rastogi V, Proaño-Zamudio JA, Argandykov D, Marcaccio CL, Giannakopoulos GF, et al. Early versus delayed thoracic endovascular aortic repair for blunt thoracic aortic injury: a propensity score-matched analysis. *Ann Surg* 2023;**278**:e848–54.
- 275 Zambetti BR, Zickler WP, Lewis RH Jr, Pettigrew BD, Valaulikar GS, Afzal MO, et al. Delayed endovascular repair with procedural anticoagulation: a safe strategy for blunt aortic injury. *Ann Vasc Surg* 2022;**84**:195–200.
- 276 Kato N, Dake MD, Miller DC, Semba CP, Mitchell RS, Razavi MK, et al. Traumatic thoracic aortic aneurysm: treatment with endovascular stent-grafts. *Radiology* 1997;**205**:657–62.
- 277 Tang GL, Tehrani HY, Usman A, Katariya K, Otero C, Perez E, et al. Reduced mortality, paraplegia, and stroke with stent graft repair of blunt aortic transections: a modern meta-analysis. *J Vasc Surg* 2008;**47**:671–5.
- 278 van der Zee CP, Vainas T, van Brussel FA, Tielliu IF, Zeebregts CJ, van der Laan MJ. Endovascular treatment of traumatic thoracic aortic lesions: a systematic review and meta-analysis. *J Cardiovasc Surg (Torino)* 2019;**60**:100–10.
- 279 García Reyes ME, Gonçalves Martins G, Fernández Valenzuela V, Domínguez González JM, Maeso Lebrun J, Bellmunt Montoya S. Long-term outcomes of thoracic endovascular aortic repair focused on bird beak and oversizing in blunt traumatic thoracic aortic injury. *Ann Vasc Surg* 2018;**50**:140–7.
- 280 Lettinga-van de Poll T, Schurink GW, De Haan MW, Verbruggen JP, Jacobs MJ. Endovascular treatment of traumatic rupture of the thoracic aorta. *Br J Surg* 2007;**94**:525–33.
- 281 Bae M, Jeon CH. Optimal sizing of aortic stent graft for blunt thoracic aortic injury considering hypotension-related decrease in aortic diameter. *J Endovasc Ther* 2024;**31**:651–7.
- 282 Smith JA, Bose S, Sarode A, Cho JS, Colvard B. Effect of intravascular ultrasound on clinical outcomes after thoracic endovascular aortic repair for blunt thoracic aortic injury. *J Vasc Surg* 2022;**75**:448–454.e2.
- 283 Ceja-Rodríguez M, Realyvasquez A, Galante J, Pevec WC, Humphries M. Differences in aortic diameter measurements with intravascular ultrasound and computed tomography after blunt traumatic aortic injury. *Ann Vasc Surg* 2018;**50**:148–53.
- 284 Borsa JJ, Hoffer EK, Karmy-Jones R, Fontaine AB, Bloch RD, Yoon JK, et al. Angiographic description of blunt traumatic injuries to the thoracic aorta with specific relevance to endograft repair. *J Endovasc Ther* 2002;**9**(Suppl. 2):II84–91.
- 285 Jonker FH, Schlosser FJ, Geirsson A, Sumpio BE, Moll FL, Muhs BE. Endograft collapse after thoracic endovascular aortic repair. *J Endovasc Ther* 2010;**17**:725–34.
- 286 Muhs BE, Balm R, White GH, Verhagen HJM. Anatomic factors associated with acute endograft collapse after Gore TAG treatment of thoracic aortic dissection or traumatic rupture. *J Vasc Surg* 2007;**45**:655–61.
- 287 Mesar T, Alie-Cusson FS, Lin MJ, Dexter DJ, Rathore A, Stokes GK, et al. Impact of thoracic endovascular aortic repair timing on aortic remodeling in acute type B aortic intramural hematoma. *J Vasc Surg* 2022;**75**:464–72.e2.
- 288 Gennai S, Leone N, Andreoli F, Munari E, Berchiolli R, Arcuri L. Influence of thoracic endovascular repair on aortic morphology in patients treated for blunt traumatic aortic injuries: long term outcomes in a multicentre study. *Eur J Vasc Endovasc Surg* 2020;**59**:428–36.
- 289 McBride CL, Dubose JJ, Miller CC 3rd, Perlick AP, Charlton-Ouw KM, Estrera AL, et al. Intentional left subclavian artery coverage during thoracic endovascular aortic repair for traumatic aortic injury. *J Vasc Surg* 2015;**61**:73–9.
- 290 Kritayakirana K, Uthapaisanwong A, Narueponjirakul N, Aimsupanimitr P, Kittayarak C, Yu J. Coverage of the left subclavian artery in blunt thoracic aortic injury repair is rarely indicated. *Ann Vasc Surg* 2022;**87**:461–8.
- 291 Chen X, Wang J, Premaratne S, Zhao J, Zhang WW. Meta-analysis of the outcomes of revascularization after intentional coverage of the left subclavian artery for thoracic endovascular aortic repair. *J Vasc Surg* 2019;**70**:1330–40.
- 292 Sepehrpour AH, Ahmed K, Vecht JA, Anagnostakou V, Suliman A, Ashrafian H, et al. Management of the left subclavian artery during endovascular stent grafting for traumatic aortic injury – a systematic review. *Eur J Vasc Endovasc Surg* 2011;**41**:758–69.
- 293 Rizvi AZ, Murad MH, Fairman RM, Erwin PJ, Montori VM. The effect of left subclavian artery coverage on morbidity and mortality in patients undergoing endovascular thoracic aortic interventions: a systematic review and meta-analysis. *J Vasc Surg* 2009;**50**:1159–69.
- 294 Matsumura JS, Rizvi AZ, Society for Vascular Surgery. Left subclavian artery revascularization: Society for Vascular Surgery practice guidelines. *J Vasc Surg* 2010;**52**(4 Suppl):65S–70S.
- 295 Romagnoli AN, Paterson J, Dua A, Kauvar D, Saqib N, Miller C, et al. Cover with caution: management of the left subclavian artery in TEVAR for trauma. *J Trauma Acute Care Surg* 2023;**94**:392–7.
- 296 Kruger JL, Balceniuk MD, Zhao P, Ayers BC, Ellis JL, Doyle AJ, et al. Left subclavian artery coverage is not associated with neurological deficits in trauma patients undergoing thoracic endovascular repair. *Ann Vasc Surg* 2022;**86**:408–16.
- 297 Redlinger RE Jr, Ahanchi SS, Panneton JM. In situ laser fenestration during emergent thoracic endovascular aortic repair is an effective method for left subclavian artery revascularization. *J Vasc Surg* 2013;**58**:1171–7.
- 298 Nana P, Le Houérou T, Rockley M, Guihaire J, Gaudin A, Costanzo A, et al. Early and midterm outcomes of endovascular aortic arch repair using in situ laser fenestration. *J Endovasc Ther* 2024; doi: 10.1177/15266028241234497 [epub ahead of print].
- 299 Lounes Y, Belarbi A, Hireche K, Chassin-Trubert L, Ozdemir BA, Akodad M, et al. Physician-modified stent graft for blunt thoracic aortic injuries: do the benefits worth the trouble? *Ann Vasc Surg* 2023;**90**:100–8.
- 300 von Oppell UO, Dunne TT, De Groot KM, Zilla P. Spinal cord protection in the absence of collateral circulation: meta-analysis of mortality and paraplegia. *J Card Surg* 1994;**9**:685–91.
- 301 von Oppell UO, Dunne TT, De Groot MK, Zilla P. Traumatic aortic rupture: twenty-year metaanalysis of mortality and risk of paraplegia. *Ann Thorac Surg* 1994;**58**:585–93.
- 302 Estrera AL, Miller CC 3rd, Guajardo-Salinas G, Coogan S, Charlton-Ouw K, Safi HJ, et al. Update on blunt thoracic aortic injury: fifteen-year single-institution experience. *J Thorac Cardiovasc Surg* 2013;**145**(3 Suppl.):S154–8.
- 303 Vassileva J, Holmberg O. Radiation protection perspective to recurrent medical imaging: what is known and what more is needed? *Br J Radiol* 2021;**94**:20210477.

- 304 Guala A, Gil-Sala D, Garcia Reyes ME, Azancot MA, Dux-Santoy L, Allegue Allegue N, et al. Impact of thoracic endovascular aortic repair following blunt traumatic thoracic aortic injury on blood pressure. *J Thorac Cardiovasc Surg* 2024;**168**:1428–37.e3.
- 305 Canaud L, Alric P, Desgranges P, Marzelle J, Marty-Ané C, Becquemin JP. Factors favoring stent-graft collapse after thoracic endovascular aortic repair. *J Thorac Cardiovasc Surg* 2010;**139**:1153–7.
- 306 Canaud L, Marty-Ané C, Ziza V, Branchereau P, Alric P. Minimum 10-year follow-up of endovascular repair for acute traumatic transection of the thoracic aorta. *J Thorac Cardiovasc Surg* 2015;**149**:825–9.
- 307 Kuo MC, Meena RA, Ramos CR, Benarroch-Gampel J, Leshnowar BG, Duwayri Y, et al. Stent graft oversizing is associated with an increased risk of long-term left ventricular wall thickening in young patients following thoracic endovascular aortic repair. *Ann Vasc Surg* 2021;**76**:66–72.
- 308 Tigkiriopoulos K, Sigala F, Tsilimigras DI, Moris D, Filis K, Melas N, et al. Endovascular repair of blunt thoracic aortic trauma: is postimplant hypertension an incidental finding? *Ann Vasc Surg* 2018;**50**:160–6.e1.
- 309 Gennai S, Leone N, Mezzetto L, Veraldi GF, Santi D, Spaggiari G, et al. Systematic review and meta-analysis of long-term reintervention following thoracic endovascular repair for blunt traumatic aortic injury. *J Vasc Surg* 2023;**78**:540–7.e4.
- 310 Khoynezhad A, Azizzadeh A, Donayre CE, Matsumoto A, Velazquez O, RESCUE Investigators, et al. Results of a multicenter, prospective trial of thoracic endovascular aortic repair for blunt thoracic aortic injury (RESCUE trial). *J Vasc Surg* 2013;**57**:899–905.e1.
- 311 Spiliotopoulos K, Kokotsakis J, Argiriou M, Dedeilias P, Farsaris D, Diamantis T, et al. Endovascular repair for blunt thoracic aortic injury: 11-year outcomes and postoperative surveillance experience. *J Thorac Cardiovasc Surg* 2014;**148**:2956–61.
- 312 Steuer J, Björck M, Sonesson B, Resch T, Dias N, Hultgren R, et al. Editor's Choice – Durability of endovascular repair in blunt traumatic thoracic aortic injury: long-term outcome from four tertiary referral centers. *Eur J Vasc Endovasc Surg* 2015;**50**:460–5.
- 313 Makaloski V, Spanos K, Schmidli J, Köbel T. Surveillance after endovascular treatment for blunt thoracic aortic injury. *Eur J Vasc Endovasc Surg* 2018;**55**:303–4.
- 314 Mosquera VX, Marini M, Lopez-Perez JM, Muñoz-Garcia J, Herrera JM, Cao I, et al. Role of conservative management in traumatic aortic injury: comparison of long-term results of conservative, surgical, and endovascular treatment. *J Thorac Cardiovasc Surg* 2011;**142**:614–21.
- 315 Madigan MC, Lewis AJ, Liang NL, Handzel R, Hager E, Makaroun MS, et al. Outcomes of operative and nonoperative management of blunt thoracic aortic injury. *J Vasc Surg* 2022;**76**:239–247.e1.
- 316 Symbas PJ, Horsley WS, Symbas PN. Rupture of the ascending aorta caused by blunt trauma. *Ann Thorac Surg* 1998;**66**:113–7.
- 317 Grzeda AL, Moseley MD, Sangroula D, Wayne EJ, Dwivedi AJ, Sigdel A. Endovascular treatment of innominate artery bifurcation injury with balloon-expandable covered stents utilizing kissing stent technique. *Am Surg* 2023;**89**:2832–4.
- 318 Gomez CR, May AK, Terry JB, Tulyapronchote R. Endovascular therapy of traumatic injuries of the extracranial cerebral arteries. *Crit Care Clin* 1999;**15**:789–809.
- 319 Slocum C, Chiba H, Emigh B, Tam B, Schellenberg M, Inaba K, et al. Nationwide analysis of penetrating thoracic aortic injury: injury patterns, management, and outcomes. *J Surg Res* 2023;**284**:290–5.
- 320 Clarke DL, Quazi MA, Reddy K, Thomson SR. Emergency operation for penetrating thoracic trauma in a metropolitan surgical service in South Africa. *J Thorac Cardiovasc Surg* 2011;**142**:563–8.
- 321 Bastos R, Baisden CE, Harker L, Calhoun JH. Penetrating thoracic trauma. *Semin Thorac Cardiovasc Surg* 2008;**20**:19–25.
- 322 Carrick MM, Morrison CA, Pham HQ, Norman MA, Marvin B, Lee J, et al. Modern management of traumatic subclavian artery injuries: a single institution's experience in the evolution of endovascular repair. *Am J Surg* 2010;**199**:28–34.
- 323 Branco BC, DuBose JJ. Endovascular solutions for the management of penetrating trauma: an update on REBOA and axillo-subclavian injuries. *Eur J Trauma Emerg Surg* 2016;**42**:687–94.
- 324 Shalhub S, Starnes BW, Hatsukami TS, Karmy-Jones R, Tran NT. Repair of blunt thoracic outlet arterial injuries: an evolution from open to endovascular approach. *J Trauma* 2011;**71**:E114–21.
- 325 DuBose JJ, Rajani R, Gilani R, Arthurs ZA, Morrison JJ, Clouse WD, et al. Endovascular management of axillo-subclavian arterial injury: a review of published experience. *Injury* 2012;**43**:1785–92.
- 326 Desai SS, DuBose JJ, Parham CS, Charlton-Ouw KM, Valdes J, Estrera AL, et al. Outcomes after endovascular repair of arterial trauma. *J Vasc Surg* 2014;**60**:1309–14.
- 327 Torres IO, Lourenço de Andrade RC, Apoloni R, Simão da Silva E, Puech-Leão P, De Luccia N. Editor's Choice – In hospital and long term outcomes after repair of subclavian and axillary artery injuries. *Eur J Vasc Endovasc Surg* 2023;**66**:840–7.
- 328 Zambetti BR, Stuber JD, Patel DD, Lewis RH Jr, Huang DD, Zickler WP, et al. Impact of endovascular stenting on outcomes in patients with traumatic subclavian artery injury. *J Am Coll Surg* 2022;**234**:444–9.
- 329 Waller CJ, Cogbill TH, Kallies KJ, Ramirez LD, Cardenas JM, Todd SR. Contemporary management of subclavian and axillary artery injuries—a Western Trauma Association multicenter review. *J Trauma Acute Care Surg* 2017;**83**:1023–31.
- 330 Hanif H, Clark R, Moore S, Morrell NT, Marek J, Rana MA, et al. Long-term outcomes of open and endovascular axillosubclavian interventions after traumatic injury reveal high rates of limb dysfunction. *Ann Vasc Surg* 2023;**97**:392–8.
- 331 Tyburski JG, Wilson RF, Dente C, Steffes C, Carlin AM. Factors affecting mortality rates in patients with abdominal vascular injuries. *J Trauma* 2001;**50**:1020–6.
- 332 Kobayashi L, Coimbra R, Goes AMO Jr, Reva V, Santorelli J, Moore EE, et al. American Association for the Surgery of Trauma—World Society of Emergency Surgery guidelines on diagnosis and management of abdominal vascular injuries. *J Trauma Acute Care Surg* 2020;**89**:1197–211.
- 333 Cothren CC, Moore EE. Vascular Trauma: Life-threatening thoracoabdominal injuries and limb-threatening extremity injuries. In: Bland KI, Büchler MW, Csendes A, Sarr MG, Garden OJ, Wong J, editors. *General Surgery*. London, UK: Springer; 2009. p. 109–20.
- 334 Asensio JA, Chahwan S, Hanpeter D, Demetriades D, Forno W, Gambaro E, et al. Operative management and outcome of 302 abdominal vascular injuries. *Am J Surg* 2000;**180**:528–33; discussion 533–4.
- 335 Howley IW, Stein DM, Scalea TM. Outcomes and complications for portal vein or superior mesenteric vein injury: no improvement in the era of damage control resuscitation. *Injury* 2019;**50**:2228–33.
- 336 Mosquera VX, Marini M, Cao I, Gullías D, Muñoz J, Herrera-Noreña JM, et al. Traumatic aortic injuries associated with major visceral vascular injuries in major blunt trauma patients. *World J Surg* 2012;**36**:1571–80.
- 337 Asensio JA, Petrone P, Roldán G, Kuncir E, Rowe VL, Chan L, et al. Analysis of 185 iliac vessel injuries: risk factors and predictors of outcome. *Arch Surg* 2003;**138**:1187–93.
- 338 Deree J, Shenvi E, Fortlage D, Stout P, Potenza B, Hoyt DB, et al. Patient factors and operating room resuscitation predict

- mortality in traumatic abdominal aortic injury: a 20-year analysis. *J Vasc Surg* 2007;**45**:493–7.
- 339 Magee GA, Cho J, Matsushima K, Strumwasser A, Inaba K, Jazaeri O, et al. Isolated iliac vascular injuries and outcome of repair versus ligation of isolated iliac vein injury. *J Vasc Surg* 2018;**67**:254–61.
- 340 Maturen KE, Adusumilli S, Blane CE, Arbabi S, Williams DM, Fitzgerald JT, et al. Contrast-enhanced CT accurately detects hemorrhage in torso trauma: direct comparison with angiography. *J Trauma* 2007;**62**:740–5.
- 341 Hamilton JD, Kumaravel M, Censullo ML, Cohen AM, Kievlan DS, West OC. Multidetector CT evaluation of active extravasation in blunt abdominal and pelvic trauma patients. *Radiographics* 2008;**28**:1603–16.
- 342 Willmann JK, Roos JE, Platz A, Pfammatter T, Hilfiker PR, Marincek B, et al. Multidetector CT: detection of active hemorrhage in patients with blunt abdominal trauma. *AJR Am J Roentgenol* 2002;**179**:437–44.
- 343 Yao DC, Jeffrey RB Jr, Mirvis SE, Weekes A, Federle MP, Kim C, et al. Using contrast-enhanced helical CT to visualize arterial extravasation after blunt abdominal trauma: incidence and organ distribution. *AJR Am J Roentgenol* 2002;**178**:17–20.
- 344 Sorrentino TA, Moore EE, Wohlaer MV, Biffl WL, Pieracci FM, Johnson JL, et al. Effect of damage control surgery on major abdominal vascular trauma. *J Surg Res* 2012;**177**:320–5.
- 345 Feliciano DV, Moore EE, Biffl WL. Western Trauma Association critical decisions in trauma: management of abdominal vascular trauma. *J Trauma Acute Care Surg* 2015;**79**:1079–88.
- 346 Feliciano DV. Management of traumatic retroperitoneal hematoma. *Ann Surg* 1990;**211**:109–23.
- 347 Kobayashi LM, Costantini TW, Hamel MG, Dierksheide JE, Coimbra R. Abdominal vascular trauma. *Trauma Surg Acute Care Open* 2016;**1**:e000015.
- 348 Shalhub S, Starnes BW, Brenner ML, Biffl WL, Azzizadeh A, Inaba K, et al. Blunt abdominal aortic injury: a Western Trauma Association multicenter study. *J Trauma Acute Care Surg* 2014;**77**:879–85; discussion 885.
- 349 Chang R, Drake SA, Holcomb JB, Phillips G, Wade CE, Charlton-Ouw KM. Characteristics of trauma mortality in patients with aortic injury in Harris County, Texas. *J Clin Med* 2020;**9**:2965.
- 350 Charlton-Ouw KM, DuBose JJ, Leake SS, Sanchez-Perez M, Sandhu HK, Holcomb JB, et al. Observation may be safe in selected cases of blunt traumatic abdominal aortic injury. *Ann Vasc Surg* 2016;**30**:34–9.
- 351 Harris DG, Drucker CB, Brenner ML, Sarkar R, Narayan M, Crawford RS. Patterns and management of blunt abdominal aortic injury. *Ann Vasc Surg* 2013;**27**:1074–80.
- 352 Dayama A, Rivera A, Olorunfemi O, Mahmoud A, Fontecha CA, McNelis J. Open and endovascular abdominal aortic injury repair outcomes in polytrauma patients. *Ann Vasc Surg* 2017;**42**:156–61.
- 353 Jonker FH, Verhagen HJ, Mojibian H, Davis KA, Moll FL, Muhs BE. Aortic endograft sizing in trauma patients with hemodynamic instability. *J Vasc Surg* 2010;**52**:39–44.
- 354 Cestero RF, Plurad D, Green D, Inaba K, Putty B, Benfield R, et al. Iliac artery injuries and pelvic fractures: a national trauma database analysis of associated injuries and outcomes. *J Trauma* 2009;**67**:715–18.
- 355 Ball CG, Feliciano DV. Damage control techniques for common and external iliac artery injuries: have temporary intravascular shunts replaced the need for ligation? *J Trauma* 2010;**68**:1117–20.
- 356 DuBose J, Inaba K, Barmparas G, Teixeira PG, Schnuriger B, Talving P, et al. Bilateral internal iliac artery ligation as a damage control approach in massive retroperitoneal bleeding after pelvic fracture. *J Trauma* 2010;**69**:1507–14.
- 357 Kufner S, Cassese S, Groha P, Byrne RA, Schunkert H, Kastrati A, et al. Covered stents for endovascular repair of iatrogenic injuries of iliac and femoral arteries. *Cardiovasc Revasc Med* 2015;**16**:156–62.
- 358 Ruffino MA, Fronda M, Varello S, Discalzi A, Mancini A, Muratore P, et al. Emergency management of iatrogenic arterial injuries with a low-profile balloon-expandable stent-graft: preliminary results. *Medicine (Baltimore)* 2020;**99**:e19655.
- 359 Velmahos GC, Chahwan S, Hanks SE, Murray JA, Berne TV, Asensio J, et al. Angiographic embolization of bilateral internal iliac arteries to control life-threatening hemorrhage after blunt trauma to the pelvis. *Am Surg* 2000;**66**:858–62.
- 360 Fu CY, Wang YC, Wu SC, Chen RJ, Hsieh CH, Huang HC, et al. Angioembolization provides benefits in patients with concomitant unstable pelvic fracture and unstable hemodynamics. *Am J Emerg Med* 2012;**30**:207–13.
- 361 Bonde A, Velmahos A, Kalva SP, Mendoza AE, Kaafarani HMA, Nederpelt CJ. Bilateral internal iliac artery embolization for pelvic trauma: effectiveness and safety. *Am J Surg* 2020;**220**:454–8.
- 362 Maithel S, Grigorian A, Fujitani RM, Kabutey NK, Sheehan BM, Gambhir S, et al. Incidence, morbidity, and mortality of traumatic superior mesenteric artery injuries compared to other visceral arteries. *Vascular* 2020;**28**:142–51.
- 363 Evans S, Talbot E, Hellenenthal N, Monie D, Campbell P, Cooper S. Mesenteric vascular injury in trauma: an NTDB study. *Ann Vasc Surg* 2021;**70**:542–8.
- 364 Asensio JA, Petrone P, Garcia-Nuñez L, Healy M, Martin M, Kuncir E. Superior mesenteric venous injuries: to ligate or to repair remains the question. *J Trauma* 2007;**62**:668–75.
- 365 Erlich T, Kitrey ND. Renal trauma: the current best practice. *Ther Adv Urol* 2018;**10**:295–303.
- 366 Kurniawan A, Adi K. Blunt renal trauma in ureteropelvic junction obstruction kidney: a case report. *Int J Surg Case Rep* 2022;**94**:107005.
- 367 Morey AF, Broghammer JA, Hollowell CMP, McKibben MJ, Souter L. Urotrauma guideline 2020: AUA guideline. *J Urol* 2021;**205**:30–5.
- 368 Keihani S, Xu Y, Presson AP, Hotaling JM, Nirula R, Piotrowski J, et al. Contemporary management of high-grade renal trauma: results from the American Association for the Surgery of Trauma genitourinary trauma study. *J Trauma Acute Care Surg* 2018;**84**:418–25.
- 369 Clark DE, Georgitis JW, Ray FS. Renal arterial injuries caused by blunt trauma. *Surgery* 1981;**90**:87–96.
- 370 Coccolini F, Moore EE, Kluger Y, Biffl W, Leppaniemi A, WSES-AAST Expert Panel, et al. Kidney and uro-trauma: WSES-AAST guidelines. *World J Emerg Surg* 2019;**14**:54.
- 371 Alzerwi NAN. Traumatic injuries to the renal blood vessels and in-hospital renal complications in patients with penetrating or blunt trauma. *Front Surg* 2023;**10**:1134945.
- 372 Bruce LM, Croce MA, Santaniello JM, Miller PR, Lyden SP, Fabian TC. Blunt renal artery injury: incidence, diagnosis, and management. *Am Surg* 2001;**67**:550–4; discussion 555–6.
- 373 Javanmard B, Fallah-Karkan M, Razzaghi M, Djafari AA, Ghiyasi S, Lotfi B, et al. Characteristics of traumatic urogenital injuries in emergency department; a 10-year cross-sectional study. *Arch Acad Emerg Med* 2019;**7**:e63.
- 374 Ouriel K, Andrus CH, Ricotta JJ, DeWeese A, Green RM. Acute renal artery occlusion: when is revascularization justified? *J Vasc Surg* 1987;**5**:348–55.
- 375 Hass CA, Dinchman KH, Nasrallah PF, Resnick S. Traumatic renal artery occlusion: a 15-year review. *J Trauma* 1998;**45**:557–61.
- 376 Jawas A, Abu-Zidan FM. Management algorithm for complete blunt renal artery occlusion in multiple trauma patients: case series. *Int J Surg* 2008;**6**:317–22.
- 377 Knudson MM, Harrison PB, Hoyt DB, Shatz DV, Zietlow SP, Bergstein JM, et al. Outcome after major renovascular injuries: a Western Trauma Association multicenter report. *J Trauma* 2000;**49**:1116–22.

- 378 Tillou A, Romero J, Asensio JA, Best CD, Petrone P, Roldan G, et al. Renal vascular injuries. *Surg Clin North Am* 2001;**81**:1417–30.
- 379 Santucci RA, Fisher MB. The literature increasingly supports expectant (conservative) management of renal trauma—a systematic review. *J Trauma* 2005;**59**:493–503.
- 380 Liguori G, Rebez G, Larcher A, Rizzo M, Cai T, Trombetta C, et al. The role of angioembolization in the management of blunt renal injuries: a systematic review. *BMC Urol* 2021;**21**:104.
- 381 Balachandran G, Bharathy KGS, Sikora SS. Penetrating injuries of the inferior vena cava. *Injury* 2020;**51**:2379–89.
- 382 Navsaria PH, Bruyn P, Nicol AJ. Penetrating abdominal vena cava injuries. *Eur J Vasc Endovasc Surg* 2005;**30**:499–503.
- 383 Matsumoto S, Jung K, Smith A, Coimbra R. Management of IVC injury: repair or ligation? A propensity score matching analysis using the National Trauma Data Bank. *J Am Coll Surg* 2018;**226**:752–9.e2.
- 384 Ksycki M, Ruiz G, Perez-Alonso AJ, Sciarretta JD, Gonzalo R, Iglesias E, et al. Iliac vessel injuries: difficult injuries and difficult management problems. *Eur J Trauma Emerg Surg* 2012;**38**:347–57.
- 385 Branco BC, Musonza T, Long MA, Chung J, Todd SR, Wall MJ Jr, et al. Survival trends after inferior vena cava and aortic injuries in the United States. *J Vasc Surg* 2018;**68**:1880–8.
- 386 Pinto F, Alouidor R, Theodore S. Non-operative management of an isolated blunt traumatic retrohepatic inferior vena cava injury. *Cureus* 2023;**15**:e36746.
- 387 Choi D, Kang BH, Jung K, Lim SH, Moon J. Risk factors and management of blunt inferior vena cava injury: a retrospective study. *World J Surg* 2023;**47**:2347–55.
- 388 Khan IR, Hamidian Jahromi A, Khan FM, Youssef AM. Nonoperative management of contained retrohepatic caval injury. *Ann Vasc Surg* 2012;**26**:420.e9–12.
- 389 Byerly S, Tamariz L, Lee EE, Parreco J, Nemeth Z, Palacio A, et al. A systematic review and meta-analysis of ligation versus repair of inferior vena cava injuries. *Ann Vasc Surg* 2021;**75**:489–96.
- 390 Byerly S, Cheng V, Plotkin A, Matsushima K, Inaba K, Magee GA. Impact of inferior vena cava ligation on mortality in trauma patients. *J Vasc Surg Venous Lymphat Disord* 2019;**7**:793–800.
- 391 Sullivan PS, Dente CJ, Patel S, Carmichael M, Srinivasan JK, Wyrzykowski AD, et al. Outcome of ligation of the inferior vena cava in the modern era. *Am J Surg* 2010;**199**:500–6.
- 392 Zargarán D, Zargarán A, Khan M. Systematic review of the management of retro-hepatic inferior vena cava injuries. *Open Access Emerg Med* 2020;**12**:163–71.
- 393 Smeets RR, Demir D, van Laanen J, Schurink GWH, Mees BME. Use of covered stent grafts as treatment of traumatic venous injury to the inferior vena cava and iliac veins: a systematic review. *J Vasc Surg Venous Lymphat Disord* 2021;**9**:1577–87.e1.
- 394 Pearl J, Chao A, Kennedy S, Paul B, Rhee P. Traumatic injuries to the portal vein: case study. *J Trauma* 2004;**56**:779–82.
- 395 Fraga GP, Bansal V, Fortlage D, Coimbra R. A 20-year experience with portal and superior mesenteric venous injuries: has anything changed? *Eur J Vasc Endovasc Surg* 2009;**37**:87–91.
- 396 Coimbra R, Filho AR, Nesser RA, Rasslan S. Outcome from traumatic injury of the portal and superior mesenteric veins. *Vasc Endovascular Surg* 2004;**38**:249–55.
- 397 Paul JS, Webb TP, Aprahamian C, Weigelt JA. Intraabdominal vascular injury: are we getting any better? *J Trauma* 2010;**69**:1393–7.
- 398 Owen AR, Stanley AJ, Vijayanathan A, Moss JG. The transjugular intrahepatic portosystemic shunt (TIPS). *Clin Radiol* 2009;**64**:664–74.
- 399 Yahn C, Haqqani MH, Alonso A, Kobzeva-Herzog A, Cheng TW, King EG, et al. Long-term functional outcomes of upper extremity civilian vascular trauma. *J Vasc Surg* 2024;**79**:526–31.
- 400 Abou-Sayed H, Berger DL. Blunt lower-extremity trauma and popliteal artery injuries: revisiting the case for selective arteriography. *Arch Surg* 2002;**137**:585–9.
- 401 Joseph TI, Ratnakanthan PJ, Paul E, Clements W. Utility of computed tomography angiography in traumatic lower limb injury: review of clinical impact in level 1 trauma centre. *Injury* 2021;**52**:3064–7.
- 402 Le Roux J, Burger M, Du Preez G, Ferreira N. The reliability of physical examination in diagnosing arterial injury in penetrating trauma to extremities: a first look at different anatomical regions and injury mechanisms. *S Afr Med J* 2021;**111**:891–5.
- 403 Tung L, Seamon MJ, Dauer E, Alabi O, Benarroch-Gampel J, Passman J, et al. Using arterial pressure index to predict arterial injuries in penetrating trauma to the upper extremities. *Am Surg* 2023;**89**:108–12.
- 404 Kurtoglu M, Dolay K, Karamustafaoğlu B, Yanar H, Kuzkaya M. The role of the ankle brachial pressure index in the diagnosis of peripheral arterial injury. *Ulus Travma Acil Cerrahi Derg* 2009;**15**:448–52.
- 405 Hemingway J, Adjei E, Desikan S, Gross J, Tran N, Singh N, et al. Lowering the ankle-brachial index threshold in blunt lower extremity trauma may prevent unnecessary imaging. *Ann Vasc Surg* 2020;**62**:106–13.
- 406 deSouza IS, Benabbas R, McKee S, Zangbar B, Jain A, Paladino L, et al. Accuracy of physical examination, ankle-brachial index, and ultrasonography in the diagnosis of arterial injury in patients with penetrating extremity trauma: a systematic review and meta-analysis. *Acad Emerg Med* 2017;**24**:994–1017.
- 407 Callcut RA, Acher CW, Hoch J, Tefera G, Turnipseed W, Mell MW. Impact of intraoperative arteriography on limb salvage for traumatic popliteal artery injury. *J Trauma* 2009;**67**:252–7; discussion 257–8.
- 408 Perkins ZB, Yet B, Glasgow S, Cole E, Marsh W, Brohi K, et al. Meta-analysis of prognostic factors for amputation following surgical repair of lower extremity vascular trauma. *Br J Surg* 2015;**102**:436–50.
- 409 Perkins ZB, Kersey AJ, White JM, Lauria AL, Propper BW, Tai NRM, et al. Impact of ischemia duration on lower limb salvage in combat casualties. *Ann Surg* 2022;**276**:532–8.
- 410 Chipman AM, Ottochian M, Ricaurte D, Gunter G, DuBose JJ, Stonko DP, et al. Contemporary management and time to revascularization in upper extremity arterial injury. *Vascular* 2023;**31**:284–91.
- 411 Glass GE, Pearse MF, Nanchahal J. Improving lower limb salvage following fractures with vascular injury: a systematic review and new management algorithm. *J Plast Reconstr Aesthet Surg* 2009;**62**:571–9.
- 412 Zaraca F, Ponzoni A, Stringari C, Ebner JA, Giovannetti R, Ebner H. Lower extremity traumatic vascular injury at a level II trauma center: an analysis of limb loss risk factors and outcomes. *Minerva Chir* 2011;**66**:397–407.
- 413 Hsieh YH, Lee MC, Hsu CC, Chen SH, Lin YT, Lin CH, et al. Popliteal artery injury after fracture and/or dislocation of the knee: risk stratification for revascularization outcome. *Ann Plast Surg* 2022;**88**(1s Suppl. 1):S50–5.
- 414 Lewis RH Jr, Perkins M, Fischer PE, Beebe MJ, Magnotti LJ. Timing is everything: impact of combined long bone fracture and major arterial injury on outcomes. *J Trauma Acute Care Surg* 2022;**92**:21–7.
- 415 Magnotti LJ, Sharpe JP, Tolley B, Thomas F, Lewis RH Jr, Filiberto DM, et al. Long-term functional outcomes after traumatic popliteal artery injury: a 20-year experience. *J Trauma Acute Care Surg* 2020;**88**:197–206.
- 416 Johansen K, Daines M, Howey T, Helfet D, Hansen ST Jr. Objective criteria accurately predict amputation following lower extremity trauma. *J Trauma* 1990;**30**:568–72; discussion 572–3.



- 417 Gregory RT, Gould RJ, Pecllet M, Wagner JS, Gilbert DA, Wheeler JR, et al. The Mangled Extremity Syndrome (M.E.S.): a severity grading system for multisystem injury of the extremity. *J Trauma* 1985;25:1147–50.
- 418 Nayar SK, Alcock HMF, Edwards DS. Primary amputation versus limb salvage in upper limb major trauma: a systematic review. *Eur J Orthop Surg Traumatol* 2022;32:395–403.
- 419 Yoneda H, Takeda S, Saeki M, Iwatsuki K, Yamamoto M, Tatebe M, et al. Utility of severity scoring systems for mangled upper limb salvage: a systematic review and meta-analysis. *Injury* 2024;55:111447.
- 420 Kumar RS, Singhi PK, Chidambaram M. Are we justified doing salvage or amputation procedure based on Mangled Extremity Severity Score in mangled upper extremity injury. *J Orthop Case Rep* 2017;7:3–8.
- 421 Fochtman A, Binder H, Retzl G, Starlinger J, Aszmann O, Sarahrudi K, et al. Third degree open fractures and traumatic sub-/total amputations of the upper extremity: outcome and relevance of the Mangled Extremity Severity Score. *Orthop Traumatol Surg Res* 2016;102:785–90.
- 422 Elsharawy MA. Arterial reconstruction after mangled extremity: injury severity scoring systems are not predictive of limb salvage. *Vascular* 2005;13:114–9.
- 423 Prichayudh S, Verananvattna A, Sriussadaporn S, Sriussadaporn S, Kritayakirana K, Pak-art R, et al. Management of upper extremity vascular injury: outcome related to the Mangled Extremity Severity Score. *World J Surg* 2009;33:857–63.
- 424 Togawa S, Yamami N, Nakayama H, Mano Y, Ikegami K, Ozeki S. The validity of the Mangled Extremity Severity Score in the assessment of upper limb injuries. *J Bone Joint Surg Br* 2005;87:1516–19.
- 425 Schirò GR, Sessa S, Piccioli A, Maccauro G. Primary amputation vs limb salvage in mangled extremity: a systematic review of the current scoring system. *BMC Musculoskelet Disord* 2015;16:372.
- 426 Gratl A, Kluckner M, Gruber L, Klocker J, Wipperfurth S, Enzmann FK. The Mangled Extremity Severity Score (MESS) does not predict amputation in popliteal artery injury. *Eur J Trauma Emerg Surg* 2023;49:2363–71.
- 427 Perkins ZB, Yet B, Sharrock A, Rickard R, Marsh W, Rasmussen TE, et al. Predicting the outcome of limb revascularization in patients with lower-extremity arterial trauma: development and external validation of a supervised machine-learning algorithm to support surgical decisions. *Ann Surg* 2020;272:564–72.
- 428 Loja MN, Sammann A, DuBose J, Li CS, Liu Y, AAST PROOVIT Study Group, et al. The mangled extremity score and amputation: time for a revision. *J Trauma Acute Care Surg* 2017;82:518–23.
- 429 Dennis JW, Frykberg ER, Veldenz HC, Huffman S, Menawat SS. Validation of nonoperative management of occult vascular injuries and accuracy of physical examination alone in penetrating extremity trauma: 5- to 10-year follow-up. *J Trauma* 1998;44:243–52; discussion 242–3.
- 430 Pan Z, Zhang H, Li L, Jia Y, Tian R. Surgical treatment of traumatic lower limb pseudoaneurysm. *Chin J Traumatol* 2014;17:285–8.
- 431 Frykberg ER, Crump JM, Dennis JW, Vines FS, Alexander RH. Nonoperative observation of clinically occult arterial injuries: a prospective evaluation. *Surgery* 1991;109:85–96.
- 432 Asmar S, Bible L, Obaid O, Tang A, Khurram M, Castanon L, et al. Open vs endovascular treatment of traumatic peripheral arterial injury: propensity matched analysis. *J Am Coll Surg* 2021;233:131–8.e4.
- 433 Magee GA, Dubose JJ, Inaba K, Lucero L, Dirks RC, O'Banion LA. Outcomes of vascular trauma associated with an evolution in the use of endovascular management. *J Vasc Surg* 2023;78:405–10.e1.
- 434 Butler WJ, Calvo RY, Sise MJ, Bowie JM, Wessels LE, Bansal V, et al. Outcomes for popliteal artery injury repair after discharge: a large-scale population-based analysis. *J Trauma Acute Care Surg* 2019;86:173–80.
- 435 Jiang C, Chen Z, Zhao Y, Zhang WW, Zeng Q, Li F. Four-year outcomes following endovascular repair in patients with traumatic isolated popliteal artery injuries. *J Vasc Surg* 2021;73:2064–70.
- 436 Potter HA, Alfson DB, Rowe V, Wadé NB, Weaver FA, Inaba K, et al. Endovascular versus open repair of isolated superficial femoral and popliteal artery injuries. *J Vasc Surg* 2021;74:814–22.e1.
- 437 D'Alessio I, Domanin M, Bissacco D, Romagnoli S, Rimoldi P, Sammartano F, et al. Operative treatment and clinical outcomes in peripheral vascular trauma: the combined experience of two centers in the endovascular era. *Ann Vasc Surg* 2020;62:342–8.
- 438 Maleux G, Hertzen PJ, Vaninbrouckx J, Thijs M, Nijs S, Fourneau I, et al. Value of percutaneous embolotherapy for the management of traumatic vascular limb injury. *Acta Radiol* 2012;53:147–52.
- 439 Cheraghali R, Salimi J, Omrani Z. Endovascular treatment of penetrating vascular injuries. *J Surg Case Rep* 2021;2021:rjab486.
- 440 Wang Y, Zheng H, Yao W, Ju S, Bai Y, Wang C, et al. Management of traumatic peripheral artery pseudoaneurysm: a 10-year experience at a single center. *J Interv Med* 2023;6:29–34.
- 441 Worni M, Scarborough JE, Gandhi M, Pietrobon R, Shortell CK. Use of endovascular therapy for peripheral arterial lesions: an analysis of the National Trauma Data Bank from 2007 to 2009. *Ann Vasc Surg* 2013;27:299–305.
- 442 Schippers SM, Hajewski C, Glass NA, Caldwell L. Single forearm vessel injury in a perfused hand: repair or ligate? A systematic review. *Iowa Orthop J* 2018;38:159.
- 443 Lee CS, Scheidt J, Causey MW, Kauvar DS. Vascular reconstruction and limb loss in military tibial artery injuries. *Ann Vasc Surg* 2024;102:223–8.
- 444 Dua A, Desai SS, Johnston S, Chinapuvvula NR, DuBose J, Charlton-Ouw K, et al. Observation may be an inadequate approach for injured extremities with single tibial vessel run-off. *Vascular* 2015;23:468–73.
- 445 Croman M, Lamberton T, Covington A, Keeley JA. Outcomes following below knee arterial trauma. *Am Surg* 2023;89:4045–9.
- 446 Scalea JR, Crawford R, Scurci S, Danquah J, Sarkar R, Kufera J, et al. Below-the-knee arterial injury: the type of vessel may be more important than the number of vessels injured. *J Trauma Acute Care Surg* 2014;77:920–5.
- 447 Burkhardt GE, Cox M, Clouse WD, Porras C, Gifford SM, Williams K, et al. Outcomes of selective tibial artery repair following combat-related extremity injury. *J Vasc Surg* 2010;52:91–6.
- 448 Guerrero A, Gibson K, Kralovich KA, Pipinos I, Agnostopolous P, Carter Y, et al. Limb loss following lower extremity arterial trauma: what can be done proactively? *Injury* 2002;33:765–9.
- 449 Maher Z, Frank B, Saillant N, Goldenberg A, Dauer E, Hazelton JP, et al. Systemic intraoperative anticoagulation during arterial injury repair: implications for patency and bleeding. *J Trauma Acute Care Surg* 2017;82:680–6.
- 450 Loja MN, Sammann A, DuBose J, Li CS, Liu Y, Savage S, et al. The Mangled Extremity Score and amputation: time for a revision. *J Trauma Acute Care Surg* 2017;82:518–23.
- 451 O'Shea AE, Lee C, Kauvar DS. Analysis of concomitant and isolated venous injury in military lower extremity trauma. *Ann Vasc Surg* 2022;87:147–54.
- 452 Matsumoto S, Jung K, Smith A, Coimbra R. Outcomes comparison between ligation and repair after major lower extremity venous injury. *Ann Vasc Surg* 2019;54:152–60.
- 453 Byerly S, Cheng V, Plotkin A, Matsushima K, Inaba K, Magee GA. Impact of ligation versus repair of isolated popliteal vein injuries

- on in-hospital outcomes in trauma patients. *J Vasc Surg Venous Lymphat Disord* 2020;**8**:437–44.
- 454 Manley NR, Magnotti LJ, Fabian TC, Croce MA, Sharpe JP. Impact of venorrhaphy and vein ligation in isolated lower-extremity venous injuries on venous thromboembolism and edema. *J Trauma Acute Care Surg* 2018;**84**:325–9.
- 455 Farber A, Tan TW, Hamburg NM, Kalish JA, Joglar F, Onigman T. Early fasciotomy in patients with extremity vascular injury is associated with decreased risk of adverse limb outcomes: a review of the National Trauma Data Bank. *Injury* 2012;**43**:1486–91.
- 456 Grigorian A, Kabutey NK, de Virgilio C, Lekawa M, Schubl S, Martin M, et al. Combined arterial and venous lower extremity injury. *JAMA Surg* 2023;**158**:1346–7.
- 457 Kluckner M, Gratl A, Gruber L, Frech A, Gummerer M, Enzmann FK, et al. Predictors for the need for fasciotomy after arterial vascular trauma of the lower extremity. *Injury* 2021;**52**:2160–5.
- 458 von Keudell AG, Weaver MJ, Appleton PT, Bae DS, Dyer GSM, Heng M, et al. Diagnosis and treatment of acute extremity compartment syndrome. *Lancet* 2015;**386**:1299–310.
- 459 Gourgiotis S, Villias C, Germanos S, Foukas A, Ridolfini MP. Acute limb compartment syndrome: a review. *J Surg Educ* 2007;**64**:178–86.
- 460 Williams AB, Luchette FA, Papaconstantinou HT, Lim E, Hurst JM, Johannigman JA, et al. The effect of early versus late fasciotomy in the management of extremity trauma. *Surgery* 1997;**122**:861–6.
- 461 Rothenberg KA, George EL, Trickey AW, Chandra V, Stern JR. Delayed fasciotomy is associated with higher risk of major amputation in patients with acute limb ischemia. *Ann Vasc Surg* 2019;**59**:195–201.
- 462 Gordon WT, Talbot M, Shero JC, Osier CJ, Johnson AE, Balsamo LH, et al. Acute extremity compartment syndrome and the role of fasciotomy in extremity war wounds. *Mil Med* 2018;**183**(Suppl. 2):108–11.
- 463 Percival TJ, Patel S, Markov NP, Morrison JJ, Spencer JR, Ross JD, et al. Prophylactic fasciotomy in a porcine model of extremity trauma. *J Surg Res* 2015;**193**:449–57.
- 464 Rao AS, Scalea TM, Feliciano DV, Harfouche MN. More harm than good: it is time to reconsider prophylactic fasciotomy in lower-extremity vascular injury. *Am Surg* 2024; doi: 10.1177/00031348241244629 [pub ahead of print].
- 465 Moran BJ, Quintana MT, Scalea TM, DuBose J, Feliciano DV. Two urgency categories, same outcome: no difference after "therapeutic" vs. "prophylactic" fasciotomy. *Am Surg* 2023;**89**:614–20.
- 466 Keating JJ, Klingensmith N, Moren AM, Skarupa DJ, Loria A, Maher Z, et al. Dispelling dogma: American Association for Surgery of Trauma prospective, multicenter trial of index vs delayed fasciotomy after extremity trauma. *J Am Coll Surg* 2023;**236**:1037–44.
- 467 Bible JE, McClure DJ, Mir HR. Analysis of single-incision versus dual-incision fasciotomy for tibial fractures with acute compartment syndrom. *J Orthop Trauma* 2013;**27**:607–11.
- 468 Etemad-Rezaie A, Yang S, Kirklys M, Higginbotham DO, Zalikhha AK, Nasr K. Single incision fasciotomy for acute compartment syndrome of the leg: a systematic review of the literature. *J Orthop* 2022;**31**:134–9.
- 469 Dorweiler B, Neufang A, Schmiedt W, Hessmann MH, Rudig L, Rommens PM, et al. Limb trauma with arterial injury: long-term performance of venous interposition grafts. *Thorac Cardiovasc Surg* 2003;**51**:67–72.
- 470 Piffaretti G, Tozzi M, Lomazzi C, Rivolta N, Caronno R, Laganà D, et al. Endovascular treatment for traumatic injuries of the peripheral arteries following blunt trauma. *Injury* 2007;**38**:1091–7.
- 471 Fairhurst PG, Wyss TR, Weiss S, Becker D, Schmidli J, Makaloski V. Popliteal vessel trauma: surgical approaches and the vessel-first strategy. *Knee* 2018;**25**:849–55.
- 472 Trellopoulos G, Georgiadis GS, Aslanidou EA, Nikolopoulos ES, Pitta X, Papachristodoulou A, et al. Endovascular management of peripheral arterial trauma in patients presenting in hemorrhagic shock. *J Cardiovasc Surg (Torino)* 2012;**53**:495–506.
- 473 Sarpe AK, Flumignan CD, Nakano LC, Trevisani VF, Lopes RD, Guedes Neto HJ, et al. Duplex ultrasound for surveillance of lower limb revascularisation. *Cochrane Database Syst Rev* 2023;**7**:CD013852.
- 474 Abu Dabrh AM, Mohammed K, Farah W, Haydour Q, Zierler RE, Wang Z, et al. Systematic review and meta-analysis of duplex ultrasound surveillance for infrainguinal vein bypass grafts. *J Vasc Surg* 2017;**66**:1885–91.e8.
- 475 Heis HA, Bani-Hani KE, Elheis MA. Overview of extremity arterial trauma in Jordan. *Int Angiol* 2008;**27**:522–8.
- 476 Twine CP, Kakkos SK, Aboyans V, Baumgartner I, Behrendt CA, Bellmunt-Montoya S, et al. Editor's Choice – European Society for Vascular Surgery (ESVS) 2023 clinical practice guidelines on antithrombotic therapy for vascular diseases. *Eur J Vasc Endovasc Surg* 2023;**65**:627–89.
- 477 Khan S, Elghazaly H, Mian A, Khan M. A meta-analysis on anticoagulation after vascular trauma. *Eur J Trauma Emerg Surg* 2020;**46**:1291–9.
- 478 Argandykov D, Proano-Zamudio JA, Dorcken-Gallastegi A, Gebran A, Renne AM, Paranjape CN, et al. Timing and choice of systemic anticoagulation in the setting of extremity arterial injury repair. *Eur J Trauma Emerg Surg* 2023;**49**:473–85.
- 479 Stonko DP, Betzold RD, Azar FK, Edwards J, Abdou H, Elansary NN, et al. Postoperative antiplatelet and/or anticoagulation use does not impact complication or reintervention rates after vein repair of arterial injury: a PROOVIT study. *Vascular* 2023;**31**:777–83.
- 480 Wang E, Inaba K, Cho J, Byerly S, Rowe V, Benjamin E, et al. Do antiplatelet and anticoagulation agents matter after repair of traumatic arterial injuries? *Am Surg* 2016;**82**:968–72.
- 481 Wahlgren CM, Kragsterman B. Management and outcome of pediatric vascular injuries. *J Trauma Acute Care Surg* 2015;**79**:563–7.
- 482 Kayssi A, Metias M, Langer JC, Roche-Nagle G, Zani A, Forbes TL, et al. The spectrum and management of noniatrogenic vascular trauma in the pediatric population. *J Pediatr Surg* 2018;**53**:771–4.
- 483 Tolhurst SR, Vanderhave KL, Caird MS, Garton HL, Graziano GP, Maher CO, et al. Cervical arterial injury after blunt trauma in children: characterization and advanced imaging. *J Pediatr Orthop* 2013;**33**:37–42.
- 484 Chamoun RB, Mawad ME, Whitehead WE, Luerssen TG, Jea A. Extracranial traumatic carotid artery dissections in children: a review of current diagnosis and treatment options. *J Neurosurg Pediatr* 2008;**2**:101–8.
- 485 Jones TS, Burlew CC, Kornblith LZ, Biffi WL, Partrick DA, Johnson JL, et al. Blunt cerebrovascular injuries in the child. *Am J Surg* 2012;**204**:7–10.
- 486 Cooper A, Barlow B, Niemirska M, Gandhi R. Fifteen years' experience with penetrating trauma to the head and neck in children. *J Pediatr Surg* 1987;**22**:24–7.
- 487 Hall JR, Reyes HM, Meller JL. Penetrating zone-II neck injuries in children. *J Trauma* 1991;**31**:1614–7.
- 488 Lee TS, Ducic Y, Gordin E, Stroman D. Management of carotid artery trauma. *Craniofacial Trauma Reconstr* 2014;**7**:175–89.
- 489 Ravindra VM, Bollo RJ, Dewan MC, Riva-Cambrin JK, Tonetti D, Awad AW, et al. Comparison of anticoagulation and antiplatelet therapy for treatment of blunt cerebrovascular injury in children <10 years of age: a multicenter retrospective cohort study. *Childs Nerv Syst* 2021;**37**:47–54.
- 490 Stilwell PA, Robertson F, Bhate S, Sutcliffe AG. A child in shock: carotid blowout syndrome. *Arch Dis Child Educ Pract Ed* 2020;**105**:177–84.
- 491 Tan MA, Armstrong D, MacGregor DL, Kirton A. Late complications of vertebral artery dissection in children: pseudoaneurysm,

- thrombosis, and recurrent stroke. *J Child Neurol* 2009;24:354–60.
- 492 Heckman SR, Trooskin SZ, Burd RS. Risk factors for blunt thoracic aortic injury in children. *J Pediatr Surg* 2005;40:98–102.
- 493 Hosn MA, Nicholson R, Turek J, Sharp WJ, Pascarella L. Endovascular treatment of a traumatic thoracic aortic injury in an eight-year old patient: case report and review of literature. *Ann Vasc Surg* 2017;39:292.e1–4.
- 494 Raulli SJ, Schneider AB, Gallaher J, Motta F, Parodi E, Farber MA, et al. Trends and outcomes in management of thoracic aortic injury in children, adolescent, and mature pediatric patients using data from the National Trauma Data Bank. *Ann Vasc Surg* 2023;89:190–9.
- 495 Chiu MH, Kaitoukov Y, des Ordon AR. Late stent thrombosis in a patient with endovascular aortic repair for blunt thoracic aortic injury. *Case Rep Vasc Med* 2022;2022:5583120.
- 496 Beijer E, Scholtes VPW, Truijers M, Nederhoed JH, Yeung KK, Blankensteijn JD. Intragraft obstructive thrombus two years after endovascular repair of traumatic aortic injury: a case report and review of the literature. *EJVES Vasc Forum* 2021;53:36–41.
- 497 Hostalrich A, Canaud L, Ozdemir BA, Chaufour X. Severe thoracic aorta stenosis after endovascular treatment of blunt thoracic aortic injury. *Semin Thorac Cardiovasc Surg* 2019;31:227–9.
- 498 Bero EH, Nguyen-Ho CT, Patel PJ, Foley WD, Lee CJ. Aortic remodeling and clinical outcomes following thoracic endovascular aortic repair for blunt thoracic aortic injury. *J Surg Res* 2020;255:124–9.
- 499 Uyeda JW, Anderson SW, Sakai O, Soto JA. CT angiography in trauma. *Radiol Clin North Am* 2010;48:423–38, ix–x.
- 500 Lynch T, Kilgar J, Al Shibli A. Pediatric abdominal trauma. *Curr Pediatr Rev* 2018;14:59–63.
- 501 Delniotis I, Delniotis A, Saloupis P, Gavriilidou A, Galanis N, Kyriakou A, et al. Management of the pediatric pulseless supracondylar humeral fracture: a systematic review and comparison study of "watchful expectancy strategy" versus surgical exploration of the brachial artery. *Ann Vasc Surg* 2019;55:260–71.
- 502 Goh WCK, Ong EJY, Lee NKL, Mahadev A, Wong KPL. Systematic review of paediatric pulseless pink humerus supracondylar fractures. *J Pediatr Orthop B* 2024;33:468–76.
- 503 Griffin KJ, Walsh SR, Markar S, Tang TY, Boyle JR, Hayes PD. The pink pulseless hand: a review of the literature regarding management of vascular complications of supracondylar humeral fractures in children. *Eur J Vasc Endovasc Surg* 2008;36:697–702.
- 504 Kirkwood ML, Chamseddin KH, Hanson B, Timaran CH, Ali M, Jacob AD, et al. Continued ultrasound surveillance required after hand ischemia associated with trauma in children. *Ann Vasc Surg* 2018;51:119–23.
- 505 Bolourani S, Thompson D, Siskind S, Kalyon BD, Patel VM, Mussa FF. Cleaning up the MESS: can machine learning be used to predict lower extremity amputation after trauma-associated arterial injury? *J Am Coll Surg* 2021;232:102–13.e4.